

# Use of an Off the Shelf Inner Branch Thoraco-abdominal Endograft for the Treatment of Juxtarenal and Pararenal Aortic Aneurysms

Francesco Squizzato <sup>a,\*</sup>, Michele Piazza <sup>a</sup>, Giacomo Isernia <sup>b</sup>, Giovanni Pratesi <sup>c</sup>, Emanuele Gatta <sup>d</sup>, Michelangelo Ferri <sup>e</sup>, Yamume Tshomba <sup>f</sup>, Roberto Gattuso <sup>g</sup>, Gian Franco Veraldi <sup>h</sup>, Michele Antonello <sup>a</sup>, INBREED Investigators <sup>†</sup>

<sup>a</sup> Division of Vascular and Endovascular Surgery, Department of Cardiac, Thoracic, Vascular Sciences and Public Health, University of Padua, Padua, Italy

<sup>b</sup> Unit of Vascular and Endovascular Surgery, Santa Maria della Misericordia Hospital, Perugia, Italy

<sup>c</sup> Vascular and Endovascular Surgery Unit, Ospedale Policlinico San Martino, University of Genoa, Genoa, Italy

<sup>d</sup> Vascular and Endovascular Surgery Unit, Ospedali Riuniti di Ancona, Ancona, Italy

<sup>e</sup> Vascular and Endovascular Surgery Unit, Mauriziano Umberto I Hospital, Turin, Italy

<sup>f</sup> Unit of Vascular Surgery, Fondazione Policlinico Universitario A. Gemelli I.R.C.C.S., Università Cattolica del Sacro Cuore, Rome, Italy

<sup>g</sup> Department of Vascular Surgery, Umberto I Polyclinic Hospital, Sapienza University, Rome, Italy

<sup>h</sup> Vascular Surgery, Integrated University Hospital of Verona, Verona, Italy

## WHAT THIS PAPER ADDS

This multicentre study aimed to investigate the early and midterm outcomes of an off the shelf pre-loaded inner branched endograft (E-nside; Artivion, Kennesaw, GA, USA) in the treatment of juxta- and pararenal aortic aneurysms. In this real life non-sponsored registry, the use of E-nside for the treatment of juxta- and pararenal aortic aneurysms was feasible in both urgent and elective settings, with high technical success and satisfactory target vessel stability at one year. Early spinal cord ischaemia and stroke may derive from the length of aortic coverage and use of upper arm access; therefore, the use of this thoraco-abdominal device for the treatment of juxta- and pararenal aortic aneurysms should be approached with caution, especially in an elective setting.

**Objective:** To investigate outcomes of an off the shelf pre-loaded inner branched endograft (E-nside) for the treatment of juxtarenal and pararenal abdominal aortic aneurysms (JP-AAAs).

**Methods:** Data from a multicentre registry (INBREED), including patients treated with the E-nside endograft, were collected and analysed prospectively. Patients treated for JP-AAA were included. Pre-operative clinical and anatomical characteristics, procedural data, and 30 day and one year outcomes were recorded. Endpoints were technical success, 30 day death, major adverse events (MAEs), and one year freedom from target vessel instability.

**Results:** Of 185 consecutively treated patients, 47 (25.4%) had a JP-AAA (juxtarenal  $n = 10$ , 21%; pararenal  $n = 37$ , 79%) and were included in the study; 183 target vessels were incorporated through an inner branch. Procedural setting was emergency or urgent in 18 patients (38%) owing to a contained aortic rupture ( $n = 2$ , 4%), symptomatic aneurysm ( $n = 4$ , 9%), or aneurysm  $> 70$  mm ( $n = 12$ , 26%). The mean length of aortic coverage above the coeliac trunk was  $116 \pm 7$  mm. Technical success was 100% and 30 day mortality rate 4% ( $n = 2$  urgent cases). The 30 day cumulative MAE rate was 26% ( $n = 12$ ): two stroke (4%); and seven spinal cord ischaemia (15%), with six in an elective setting (21%) and one in an urgent setting (6%), and five leading to permanent paraplegia or paraparesis (10%). Freedom from target vessel instability was 99% after 30 days and  $97 \pm 3\%$  after one year.

**Conclusion:** Use of an off the shelf inner branched device for treating JP-AAA was feasible in urgent and elective settings, with high technical success and satisfactory target vessel stability at one year. In the treatment of JP-AAA, stroke and spinal cord ischaemia may be associated with arm access and the increased aortic coverage that the design brings.

**Keywords:** Abdominal aortic aneurysm, B-EVAR, Inner branch, Juxtarenal aneurysm, Off the shelf, Pararenal aneurysm


Article history: Received 13 May 2024, Accepted 18 February 2025, Available online 21 February 2025

© 2025 The Author(s). Published by Elsevier B.V. on behalf of European Society for Vascular Surgery. This is an open access article under the CC BY license (<http://creativecommons.org/licenses/by/4.0/>).

<sup>†</sup> A list of the INBREED Investigators study group is included in [Appendix A](#).

\* Corresponding author. Vascular and Endovascular Surgery Division, Padua University, Department of Cardiac, Thoracic, Vascular Sciences and Public Health, Via Giustiniani, 2 – 35128 Padua, Italy.

E-mail address: [francesco.squizzato@unipd.it](mailto:francesco.squizzato@unipd.it) (Francesco Squizzato).

 @dr\_fsquizzato

1078-5884/© 2025 The Author(s). Published by Elsevier B.V. on behalf of European Society for Vascular Surgery. This is an open access article under the CC BY license (<http://creativecommons.org/licenses/by/4.0/>).

<https://doi.org/10.1016/j.ejvs.2025.02.030>

## INTRODUCTION

Juxta- and pararenal abdominal aortic aneurysms (JP-AAAs) are characterised by the absence of a sufficient infrarenal landing zone suitable for a standard endovascular aortic repair (EVAR). The evolution of materials and techniques today allows the feasibility of several endovascular solutions for the treatment of JP-AAA, including fenestrated branched endografts (FB-EVAR), physician modified grafts, chimney EVAR, or endosutures.<sup>1,2</sup>

Off the shelf thoraco-abdominal devices were originally introduced for the treatment of thoraco-abdominal aneurysms and dissections. Available options in Europe include outer branch (t-Branch; Cook Medical, Bloomington, IN, USA) and inner branch (E-nside; Artivion, Kennesaw, GA, USA) configurations, which have been demonstrated to be safe and effective in the treatment of a broad spectrum of aortic pathologies.<sup>3–6</sup>

Off the shelf devices for the treatment of JP-AAA carry the potential advantage of a readily available endovascular option, which allows for the treatment of symptomatic patients and large aneurysms at high risk of rupture. The drawbacks are mainly related to the use of high supra-coeliac landing zones,<sup>2,7,8</sup> with the potential risk of spinal cord ischaemia (SCI), and to the narrowness of the aorta at the level of the pararenal segment, with possible branch related adverse events.<sup>9</sup> Data on the feasibility and clinical results of the treatment of JP-AAA using off the shelf thoraco-abdominal endografts are currently scarce.

This study aimed to investigate early and one year outcomes of the treatment of JP-AAA using the E-nside endograft, using data from the multicentre ItaliaN Branched Registry of E-nside Endograft (INBREED).

## MATERIALS AND METHODS

### Study design

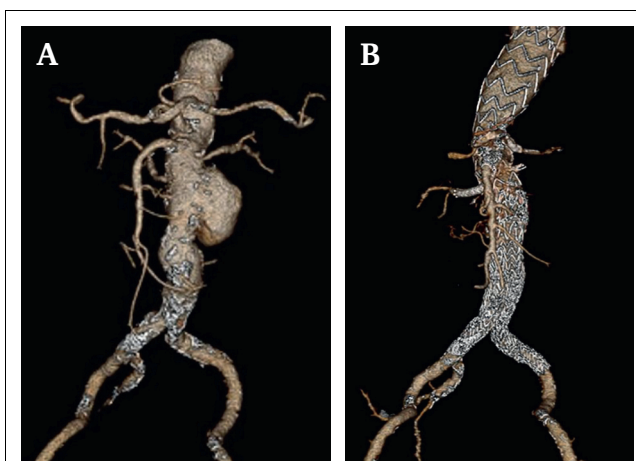
Data from a physician initiated multicentre registry including patients treated with the E-nside endograft (INBREED) were collected prospectively and analysed retrospectively.<sup>3</sup> The INBREED is a prospective, non-sponsored, multicentre, observational registry initiated in June 2021, with data collected from 35 Italian vascular centres. Data for all patients treated in each participating centre (2021 – 2024) were collected on an intention to treat basis; decisions on surgical indications, patient selection, surgical technique, and peri-operative care, including the SCI prevention protocol, were not standardised and left to each treating centre. Only patients treated for JP-AAA were included in the present analysis; those with thoraco-abdominal aneurysm (extent I to IV) or aortic dissection were excluded. Institutional review board and ethics committee approval were obtained (ID 21175).

### Data collection and definitions

Anonymised data were entered by delegates from each participating centre. No core laboratory data analysis was available, and each centre was responsible for data entry;

a senior vascular surgeon was accountable for the overall quality of data in each centre. One centre (Vascular and Endovascular Surgery Division, University of Padua, Padua, Italy) managed the research electronic data capture system (REDCap),<sup>10</sup> the quality check of the entered data, requiring audits as needed, and conducted the final data analysis for this study. A monitoring plan was implemented via audits every six months, and queries were made for specific data errors (missing, incomplete, or unclear).

Demographics, clinical characteristics, cardiovascular risk factors, operative data, and 30 day outcomes were collected. Aneurysm classification was based on extent of aneurysmal disease evaluated by computed tomography angiography (CTA) according to current reporting standards.<sup>2</sup> Other pre-operative anatomical characteristics, such as aortic diameter, target vessel stenosis, and iliac access characteristics, were assessed on the pre-operative CTA. Surgery timing was decided by the treating physician: emergency (immediate) repair was carried out in the presence of signs of rupture; an urgent repair was carried out for symptomatic non-ruptured abdominal aortic aneurysm (AAA) or aneurysms > 7 cm in diameter associated with morphological features at risk of rupture (saccular morphology, presence of concomitant penetrating aortic ulcers, pseudoaneurysm, rapid aortic growth). Major adverse events (MAEs) included severe acute kidney injury (> 50% decrease in estimated glomerular filtration rate), new onset dialysis, myocardial infarction,<sup>11</sup> respiratory failure requiring prolonged mechanical ventilation (> 48 hours) or re-intubation,<sup>12</sup> stroke, bowel ischaemia requiring surgical resection or intensive medical care, and estimated blood loss > 1 L. SCI was classified according to current reporting standards.<sup>2</sup> The imaging follow up protocol was standardised and included a CTA within one month, at six months, and twelve months (Fig. 1). Endoleaks were classified according to previously published reports.<sup>2,13</sup>



**Figure 1.** 3D reconstruction of (A) the pre-operative computed tomography angiogram (CTA) of a large pararenal aortic aneurysm; and (B) the post-operative CTA after treatment with E-nside.

### Device and technique

Detailed device design and operative technique have been described elsewhere.<sup>3,14</sup> Briefly, the E-nside is an off the shelf inner branched endograft with a 24 F outer diameter delivery system, available in four different sizes, with a proximal diameter measuring 33 or 38 mm, and a distal diameter of 26 or 30 mm. Aside from the cases treated in the early stages of the learning curve, the use of a 24 F sheath for E-nside deployment has become standard practice. The total device length is 222 mm, with 93 mm of coverage above the coeliac trunk inner branch outlet and 76 mm of coverage below the renal branch outlets. All four inner branches are pre-cannulated with a polyimide tube that can be loaded with a 0.018" wire from the handle system and snared from above the top of the graft using an upper arm or contralateral femoral approach. The use of the pre-loaded system is optional and left to the decision of the operator. By manufacturer's instructions for use, the device should land on a thoracic endograft, but, in clinical practice, it has also been safely used without thoracic endovascular aortic repair.<sup>15</sup> The choice of bridging stent was left to the discretion of the operators, but generally a balloon expandable covered stent was preferred. A bridging stent reinforcement was considered in cases with intra-operative evidence of significant kink or compression. The choice of access site for target vessel catheterisation and stenting was left to the treating surgeon. Upper arm access was used in cases with favourable anatomy of the access (axillary and subclavian artery with adequate size, free from significant obstructive disease or tortuosity), aortic arch, and descending thoracic aorta (free from significant angulation, tortuosity, or thrombus). A femoral approach was initially considered for cases with unfavourable factors for upper arm access or for cases of surgeon's preference; a progressive shift towards routine use of the femoral access was observed during the study period.

### Endpoints

Study endpoints included technical success, 30 day MAEs, and freedom from branch instability. Both endograft related and branch related technical success were evaluated according to current reporting standards.<sup>2</sup> Branch instability was defined as any target vessel related complication leading to aneurysm rupture, death, occlusion, component separation, or re-intervention to maintain target vessel patency or to treat a target vessel related component separation or endoleak.<sup>2</sup>

### Statistical analysis

Results were reported as number and percentage for categorical variables and mean  $\pm$  standard deviation for continuous variables. Continuous variables were compared with the Wilcoxon rank sum test or the *t* test, as appropriate. The Pearson chi squared test and Fisher's exact test were used for analysis of categorical variables. Univariable logistic regression was carried out to identify factors associated with any grade of SCI ( $p < .050$ ). Statistical significance was determined by  $p < .050$ . The R 4.0 software (R

Foundation for Statistical Computing, Vienna, Austria) was used for statistical analysis.

## RESULTS

### Patient population

Of the 185 patients enrolled in INBREED, 47 (25.4%) were treated for a J-AAA ( $n = 10$ , 21%) or P-AAA ( $n = 37$ , 79%). Of these, 41 (87%) had an intact asymptomatic aneurysm, four (9%) had a symptomatic aneurysm, and two (4%) had a contained rupture. The mean age was  $74 \pm 8$  years and 83% of patients were men. Other demographics and risk factors of the study cohort are presented in Table 1. The mean maximum aortic diameter was  $66 \pm 17$  mm and 15 patients (32%) presented a maximum diameter  $> 70$  mm. Significant aortic thrombus ( $> 75\%$  of aortic circumference) was present in 15 patients (32%) at the level of the paravisceral aorta and in four patients at the level of the descending thoracic aorta (9%). Other relevant anatomical details are presented in Table 2.

### Procedural data

Eighteen patients (38%) received urgent treatment owing to a contained aortic rupture ( $n = 2$ , 4%), symptomatic aneurysm ( $n = 4$ , 9%), or aneurysm size  $> 7$  cm ( $n = 12$ , 26%). Percutaneous femoral access was obtained in most patients ( $n = 27$ , 57%) for the E-nside advance and deployment. Access for target vessel cannulation was the upper arm in 38 patients (81%), whereas contralateral femoral access was used in nine cases (19%). An adjunctive proximal thoracic endograft was used in six patients (13%), and the mean length of aortic coverage above the level of the coeliac trunk was  $116 \pm 31$  mm (median 113 mm; interquartile range 95, 177 mm). A prophylactic spinal drain was placed in eight patients (17%). Endograft related technical success was achieved in all cases. Detailed procedural data are presented in Table 3.

**Table 1. Demographics and risk factors of 47 patients treated with the E-nside endograft for juxta- and pararenal aortic aneurysms in the INBREED registry.**

Variable	Patients (n = 47)
<i>Demographics</i>	
Age – y	74 $\pm$ 8
Male sex	39 (83)
<i>Risk factors</i>	
Body mass index	27.3 $\pm$ 6.4
Coronary artery disease	14 (30)
Chronic heart failure	5 (11)
Hypertension	45 (96)
Hypercholesterolaemia	36 (77)
Active or former smoker	28 (60)
Chronic obstructive pulmonary disease	25 (53)
Peripheral artery disease	11 (23)
Diabetes	7 (15)
Chronic kidney disease	11 (23)
Stroke or transient ischaemic attack	7 (15)

Data are presented as mean + standard deviation or *n* (%). INBREED = ItaliaN Branched Registry of E-nside EnDograft.

**Table 2.** Clinical and anatomical data for 47 patients treated with the E-nside endograft for juxta- and pararenal aortic aneurysms in the INBREED registry.

Variable	Patients (n = 47); target vessels (n = 188)
<i>Variables by patient</i>	
<i>Clinical data</i>	
Prior open aortic repair	5 (11)
Prior endovascular aortic repair	8 (17)
<i>Status of aortic aneurysm</i>	
Non-ruptured, asymptomatic	41 (87)
Non-ruptured, symptomatic	4 (9)
Contained rupture	2 (4)
<i>Anatomical data</i>	
<i>Aneurysm extent</i>	
Pararenal	37 (79)
Juxtarenal	10 (21)
<i>Aortic thrombus</i>	
Paravisceral aorta	15 (32)
Descending thoracic aorta	4 (9)
Maximum aortic diameter – mm	66 ± 17
Maximum aortic diameter >70 mm	15 (32)
<i>Paravisceral aortic diameter – mm</i>	
Coeliac trunk level	31 ± 6
Superior mesenteric artery level	31 ± 9
Right renal artery level	33 ± 12
Left renal artery level	35 ± 11
Paravisceral aortic diameter <24 mm	8 (17)
Minimum iliac access diameter – mm	8.5 ± 2.0
<i>Variables by target vessel</i>	
<i>Coeliac artery</i>	
Stenosis >50%	30 (25.8)
Pre-operative occlusion	5 (4.3)
<i>Superior mesenteric artery</i>	
Stenosis >50%	7 (6.0)
Pre-operative occlusion	0 (0)
<i>Right renal artery</i>	
Stenosis >50%	20 (17.2)
Pre-operative occlusion	2 (1.7)
<i>Left renal artery</i>	
Stenosis >50%	13 (11.2)
Pre-operative occlusion	3 (2.6)

Data are presented as n (%) or mean + standard deviation. INBREED = ItaliaN Branched Registry of E-nside Endograft.

All of the 188 side branches were successfully cannulated. A bridging stent was deployed in 183 target vessels (97%); five target vessels were intentionally occluded owing to a pre-operative target artery occlusion. A balloon expandable covered stent was used as the main bridging stent in 139 target vessels (76.0%); a self expandable stent was used in 44 target vessels (24.0%). Implanted balloon expandable stents were the Viabahn balloon expandable (VBX) (Gore, Flagstaff, AZ, USA) (n = 99, 71.2%), Eventus (Jotec GmbH, Hechingen, Germany) (n = 24, 17.3%), and BeGraft (Bentley InnoMed GmbH, Hechingen, Germany) (n = 16, 11.5%). Self expandable stents were the Covera (Bard, New Providence, NJ, USA) (n = 30, 68%) and Solaris (Scitech Med, Aparecida de Goiânia, Brazil) (n = 14, 32%). Bridging stent reinforcement with a bare metal stent was

**Table 3.** Procedural data for 47 patients treated with the E-nside endograft for juxta- and pararenal aortic aneurysms in the INBREED registry.

Variable	Patients (n = 47)
<i>Variables by patient</i>	
<i>Vascular access for the main endograft</i>	
Femoral, percutaneous	27 (57)
Femoral, surgical	16 (34)
Surgical iliac conduit	4 (9)
<i>Vascular access for branch bridging</i>	
Femoral, contralateral side	9 (19)
Upper arm, left side	27 (57)
Upper arm, right side	11 (23)
<i>E-nside proximal diameter</i>	
33 mm	20 (43)
38 mm	27 (57)
<i>E-nside distal diameter</i>	
26 mm	39 (83)
30 mm	8 (17)
Adjunctive proximal thoracic endograft	6 (13)
<i>Adjunctive distal abdominal endograft</i>	
Excluder, Gore	16 (34)
E-tegra, Jotec	21 (45)
Endurant, Medtronic	1 (2)
AFX2, Endologix	1 (2)
Prophylactic spinal drain	8 (17)
<i>Procedural metrics</i>	
Total operating time – min	257 (213, 317)
Total contrast volume – mL	157 (100, 200)
Total fluoroscopy time – min	89 (69, 116)
Total radiation dose – Gy*cm <sup>2</sup>	2 097 (741, 7 601)
Technical success	47 (100)
<i>Variables by target vessel</i>	
<i>Coeliac artery</i>	
Balloon expandable bridging stent	34 (72)
Self expandable bridging stent	10 (21)
Bridging stent reinforcement	7 (15)
Bridging length – mm	61 ± 12
Intentional occlusion	3 (6)
Bridging time – min	21 ± 13
<i>Superior mesenteric artery</i>	
Balloon expandable bridging stent	34 (72)
Self expandable bridging stent	13 (28)
Bridging stent reinforcement	9 (19)
Bridging length – mm	63 ± 11
Intentional occlusion	0 (0)
Bridging time – min	19 ± 13
<i>Right renal artery</i>	
Balloon expandable bridging stent	35 (74)
Self expandable bridging stent	10 (21)
Bridging stent reinforcement	10 (21)
Bridging length – mm	59 ± 16
Intentional occlusion	1 (2)
Bridging time – min	22 ± 22
<i>Left renal artery</i>	
Balloon expandable bridging stent	36 (77)
Self expandable bridging stent	8 (17)
Bridging stent reinforcement	7 (15)
Bridging length – mm	61 ± 14
Intentional occlusion	1 (2)
Bridging time – min	27 ± 38

Data are presented as n (%), median (interquartile range), or mean + standard deviation. INBREED = ItaliaN Branched Registry of E-nside Endograft.

carried out in 33 (17.6%) side branches, 17 (19%) renal arteries and 16 (18%) visceral arteries ( $p = .84$ ). The type of bridging stent per target vessel is presented in Table 3.

The mean bridging time was  $23 \pm 20$  minutes for each vessel; total operating time was  $265 \pm 128$  minutes; fluoroscopy time was  $96 \pm 54$  minutes; iodine contrast volume was  $172 \pm 123$  mL; and radiation dose was  $2\,127 \pm 403$  Gy·cm<sup>2</sup>.

### Thirty day outcomes

The 30 day mortality rate was 4% ( $n = 2$ ). Both deaths occurred in patients who were treated urgently for symptomatic P-AAA. One patient had an intra-operative cardiac arrest that was successfully cardioverted, but the patient eventually died from respiratory insufficiency 25 days after the procedure. One patient with severe chronic obstructive pulmonary disease had acute respiratory distress syndrome,<sup>16</sup> leading to death three days after the intervention. The cumulative MAE rate was 26% ( $n = 12$ ); 28% ( $n = 5$ ) in urgent and 24% ( $n = 7$ ) in elective cases ( $p = .99$ ). Detailed MAEs are presented in Table 4. Two (4%) ischaemic embolic strokes occurred, both in the posterior cerebral circulation, and both occurring in patients using left brachial access for side branch cannulation and stenting. SCI occurred in seven patients (15%), six treated in an elective setting (21%) and one in an urgent setting (6%) for a non-ruptured large aneurysm. Five patients (11%) had complete motor loss and

two (4%) had only sensory loss. None of the patients with SCI had a prophylactic spinal drain *in situ*; a therapeutic drain was then attempted in all cases. Of the two cases with sensory deficit, a spinal drain allowed for complete recovery in one patient and partial recovery in one patient. Of the five patients with motor loss, partial recovery (with residual paraparesis) occurred in two patients, with permanent paraplegia in three patients (6%). Pre-operative hypogastric artery occlusion (odds ratio [OR] 11.1, 95% confidence interval [CI] 1.24 – 139.5;  $p = .032$ ) and presence of significant thoracic or paravisceral aortic thrombus (OR 1.87, 95% CI 1.18 – 10.21;  $p = .040$ ) were significantly associated with post-operative SCI (Table 5).

Within 30 days of the index procedure, there were five re-interventions (11%) of which four (9%) were related to vascular access complications and one (2%) to a target vessel endoleak. Freedom from target vessel instability at 30 days was 99%. Target vessel adverse events were one type Ic endoleak from a right renal artery that was successfully treated with an adjunctive bridging stent, and one coeliac artery occlusion that was managed conservatively.

### One year outcomes

Median follow up was nineteen months, and 40 patients (85%) had a follow up duration of twelve months or more.

**Table 4.** Thirty day outcomes of 47 patients treated with the E-side endograft for juxta- and pararenal aortic aneurysms in the INBRED registry.

Variable	Patients ( $n = 47$ ); target vessels ( $n = 183$ )
<i>Variables by patient</i>	
<i>Medical outcomes</i>	
Death	2 (4)
Duration of hospital stay – d	7 (5, 15)
Myocardial infarction	0 (0)
Heart failure	1 (2)
Respiratory failure	4 (9)
Estimated blood loss >1 000 mL	1 (2)
Acute kidney insufficiency	4 (9)
Stroke or transient ischaemic attack	2 (4)
<i>Spinal cord ischaemia</i>	7 (15)
Motor loss	5 (11)
Sensory loss only	2 (4)
Permanent	6 (13)
Temporary	1 (2)
Gastrointestinal complications	1 (2)
<i>Surgical outcomes</i>	
<i>Early re-intervention</i>	5 (11)
Vascular access	4 (9)
Target vessel	1 (2)
Main endograft	0 (0)
<i>Variables by target vessel</i>	
Freedom from branch instability	181 (98.9)
Freedom from type I or III endoleak	182 (99.5)
Primary patency	182 (99.5)

Data presented as  $n$  (%) or median (interquartile range). INBRED = Italian Branched Registry of E-side Endograft.

**Table 5.** Univariable logistic regression for any grade of spinal cord ischaemia in 47 patients treated with the E-side endograft for juxta- and pararenal aortic aneurysms in the INBRED registry.

Characteristic	OR (95% CI)	$p$ value
Age – y	1.00 (0.90–1.14)	.95
Male sex	1.12 (0.15–23.23)	.92
Coronary artery disease	0.36 (0.02–2.45)	.37
Chronic kidney disease	1.29 (0.17–7.21)	.78
Diabetes	0.89 (0.04–6.68)	.92
Peripheral artery disease	3.32 (0.55–18.75)	.17
<i>Aneurysm anatomical classification</i>		
Juxtarenal	Ref.	–
Pararenal	0.56 (0.10–4.50)	.54
Prior aortic repair	1.12 (0.14–6.18)	.90
Staged aortic repair	1.93 (0.28–38.98)	.57
Urgent repair	1.29 (0.17–7.21)	.78
Concomitant TEVAR	1.28 (0.06–10.51)	.84
Total transfemoral access	0.23 (0.01–2.33)	.84
Length of thoracic aorta coverage	0.75 (0.34–0.96)	.37
Unilateral vertebral artery occlusion*	2.00 (0.14–6.41)	.57
Unilateral hypogastric artery occlusion†	11.1 (1.24–139.5)	.032
Thoracic and or paravisceral aortic thrombus	1.87 (1.18–10.21)	.040
Estimated blood loss >1 000 mL*	1.67 (0.11–34.57)	.77

INBRED = Italian Branched Registry of E-side Endograft; OR = odds ratio; CI = confidence interval; TEVAR = thoracic endovascular aortic repair.

\* Firth's correction owing to data separation.

Three patients were operated on less than twelve months before data collection, and two deaths occurred (other than the two post-operative deaths), both occurring in patients with post-operative paraplegia. Estimated one year survival was 91% (95% CI 83 – 99%). All alive patients received follow up imaging at 30 days, six months, and twelve months. After 30 days, there were three target vessel events (two coeliac artery endoleaks and one renal artery occlusion); the resulting freedom from target vessel instability at one year was 97% (95% CI 95 – 99%) (Fig. 2), with 99% (95% CI 97 – 100%) primary patency and 98% (95% CI 96 – 100%) freedom from endoleak. Specific freedom from target vessel instability was 93% (95% CI 85 – 100%) for the coeliac trunk, 100% for the superior mesenteric artery, 95% (95% CI 89 – 100%) for the right renal artery, and 100% for the left renal artery. There were no endoleaks or re-interventions related to the main aortic endograft during follow up.

## DISCUSSION

This study sought to investigate the outcomes of JP-AAA treatment using an inner branched thoraco-abdominal off the shelf device. The E-side achieved 100% technical success, with low mortality (0% in elective cases) and excellent target vessel stability at one year (97%). However, there was a non-negligible rate of SCI (15%, including temporary and permanent SCI) and stroke (4%), which may derive from the length of aortic coverage inherent to the device design and the high rate of brachial access use (81%). Overall, the results advise for cautious use of thoraco-abdominal devices in the treatment of juxta- and pararenal aortic pathologies. In cases in which branched endovascular aortic repair is carried out, a total transfemoral approach should be considered to prevent neurological complications.

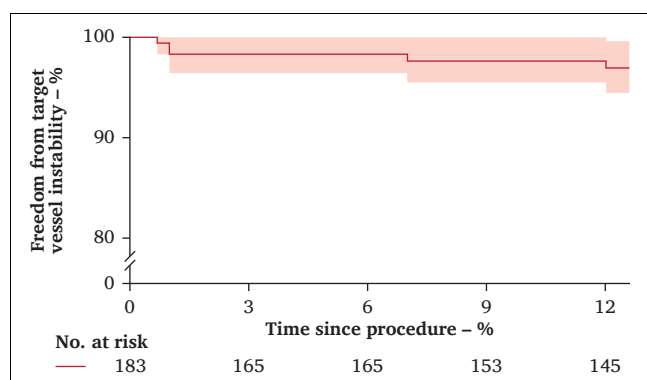
The rationale for using the E-side in JP-AAAs relies on some of its technical characteristics. The inner branched design, rather than outer branched, may allow for safe deployment, also in case of a narrow paravisceral aorta < 25 mm, minimising the risk of branch compression and occlusion.<sup>9</sup> Also, the pre-loaded system may be

advantageous in the case of challenging branch cannulation, as in a narrow and or angulated aorta;<sup>9,17</sup> the large conformation of the inner branches outlet also allows low device deployment, if needed, with the inner branch outlet positioned at the same level as the target artery onset. Finally, the availability of two proximal endograft sizes (33 and 38 mm) reduces the need for adjunctive coverage of the thoracic aorta related to a proximal tapered thoracic endograft to fit the aortic diameter.<sup>18</sup> On the other hand, the high profile (24 F) may limit its feasibility<sup>19,20</sup> and be responsible for access related complications, and the length of thoracic aortic coverage and use of upper arm access may represent possible concerns.

The main drawback of using a thoraco-abdominal off the shelf device for JP-AAA is the need for long thoracic aortic coverage for a pathology that is essentially limited to the abdominal aorta.<sup>8,21</sup> In this series, the mean supracoeliac aortic coverage length was 116 mm, which is significantly longer compared with custom made devices or physician modified endografts (PMEGs), leading to an increased risk of SCI.<sup>8,22</sup> The overall SCI rate was 15%, with a permanent partial or complete motor loss in 11%. Although this result may be biased by the small number of patients and events, the SCI rate was non-negligible, and should raise concerns on the use of off the shelf devices for JP-AAAs, especially if significant aortic thrombus or hypogastric artery occlusion are present.

The peri-operative stroke rate was 4%, which appears to be higher than that reported for open surgery (0.5 – 3%) and fenestrated endografting (1 – 2%).<sup>23,24</sup> This was essentially related to the technical choice to use brachial access for the pre-loaded wire snare, target vessel cannulation, and stenting (81% of patients).<sup>25</sup> To reduce the incidence of cerebrovascular accidents, operators should be careful in performing the snaring manoeuvres only at the level of the descending thoracic aorta and not in the aortic arch; the use of upper arm access should also be avoided in favour of a total transfemoral approach in cases with unfavourable arch anatomy or in the presence of aortic thrombus.

A possible concern in using a branched endograft for a JP-AAA is represented by side branch technical success and durability, owing to the risk of bridging stent kink, compression, or fracture in a limited aortic space.<sup>26,27</sup> In the present study, technical success related to branches was 100%, and excellent target vessel outcomes were achieved with both balloon expandable and self expandable bridging stents, in both the renal and visceral arteries. This is in line with prior experiences using inner branches,<sup>15,27,28</sup> whereas other studies have reported better outcomes using self expandable bridging stents<sup>29</sup> in thoraco-abdominal aortic aneurysm (TAAAs) treated by outer branch devices.<sup>29,30</sup> In the present study, balloon expandable stents were preferred (76% of branches), mainly because they may guarantee a higher radial force to prevent stent compression and allow for easy retrograde deployment; to date, insufficient evidence is available to support the use of a specific type of stent in inner branches, and this topic warrants further investigation.



**Figure 2.** Cumulative Kaplan–Meier estimate of one year freedom from branch instability for 183 target vessels incorporated through an inner branch using the E-side endograft. Standard error < 10.0%. The freedom from target vessel instability at one year was 97% (95% confidence interval 95 – 99%).

The 2024 European Society for Vascular Society guidelines acknowledge that off the shelf devices may be considered for the urgent treatment of complex AAAs, including symptomatic or large AAAs for which the waiting time for a custom endograft is unsafe.<sup>1,31</sup> Although off the shelf devices have been used with excellent outcomes for the treatment of extent I – IV TAAAs, the evidence supporting their use specifically for JP-AAAs remains limited.<sup>3,26,27,32</sup>

The most used device worldwide is represented by the t-Branch (Cook Medical), which has been available since 2012. The t-Branch, however, has mainly been used for the treatment of thoraco-abdominal aneurysms,<sup>22,32</sup> and the reported results obtained for TAAAs are often merged with JP-AAAs; therefore, it is difficult to extrapolate the t-Branch results in the specific setting of JP-AAAs.<sup>22</sup> Nevertheless, the t-Branch has also shown excellent results in the setting of a narrow paravisceral aorta,<sup>33</sup> and its use in patients with complex AAA is generally accepted in cases of urgent repair for patients who are unsuitable candidates for custom made fenestrated or branched devices because of symptoms, contained rupture, or an excessively large aneurysm.<sup>34,35</sup> Despite the different branch design, the E-nside and t-Branch share the need for a long thoracic coverage, and both are approved for the treatment of TAAAs only.

No direct comparisons have been made between E-nside and t-Branch for JP-AAAs, and further studies are required to compare the outcomes of these two endografts. Another possible off the shelf device is the TAMBE (W.L. Gore & Associates, Flagstaff, AZ, USA). Compared with E-nside and t-Branch, TAMBE carries the theoretical advantage of shorter thoracic coverage, and it is also approved for the treatment of P-AAAs.<sup>20</sup> The clinical evidence with TAMBE remains inadequate; the only available report was published in 2018 by Oderich *et al.*<sup>36</sup> in a series of 13 patients, of whom 10 had P-AAAs. Technical success was high (92%), with no deaths, and no target vessel instability at 30 days.<sup>8,21–24</sup>

Current European guidelines<sup>1</sup> advocate the use of off the shelf devices for the urgent repair of complex AAAs, reserving alternative solutions (such as PMEGs and *in situ* laser fenestration) only when a suitable off the shelf device is unavailable. Given the results of the present study, the risk of extensive thoracic aortic coverage should be carefully weighed against the benefit of a readily available device. Off the shelf endografts should only be considered in cases in which the provided additional coverage of the thoracic aorta is limited, particularly when a high supraceliac landing zone (> 5 cm above the coeliac trunk)<sup>2,7</sup> is needed regardless of the type of endovascular repair. Also, for ruptured aneurysms, the use of a readily available branched endograft may be reasonable, as it avoids the time needed for endograft modifications that are required for PMEGs. However, if the aneurysm can be treated using a low infrarenal landing zone<sup>2,7,37</sup> (using a PMEG or *in situ* fenestration), the risk of SCI provided by branched thoraco-abdominal repair may not be justifiable. In these cases (assuming that open repair is not feasible), a fenestrated

PMEG may be preferable, especially if it can maintain a short bridging distance between fenestrations and target arteries, and if it is carried out by an experienced team, reducing possible fenestration misalignment.<sup>38–41</sup> Also, off the shelf device modifications are described specifically to reduce aortic coverage in the treatment of JP-AAAs,<sup>34,42</sup> but their clinical outcomes are under reported. In the case of a JP-AAA with a 4 mm neck length, the use of endoanchors or the chimney graft technique may be considered.<sup>1</sup>

The results of the recent UK-COMPASS study<sup>43</sup> seem to support the use of fenestrated devices for the treatment of J-AAAs, compared with open repair or standard EVAR (outside instructions for use), as F-EVAR provides better early and midterm survival. In the present study, 28% of patients had had a prior infrarenal aortic repair (open or endovascular), and may probably have been treated with a fenestrated endograft, with a similar mortality rate. The UK-COMPASS only included elective operations and excluded patients treated by off the shelf devices; therefore, the length of aortic coverage was arguably short. Nevertheless, a non-negligible 4.4% SCI rate was observed after F-EVAR, highlighting that further research on SCI management techniques and protocols is still required.

This study had some limitations. This was a single arm study without a comparison group. The indications, procedural steps, and peri-operative clinical management were not standardised and were left to the treating centre. The number of patients excluded from E-nside treatment because of anatomical limitations is unknown. The investigated device has only recently been introduced into the market and longer follow up is unavailable. An extensive analysis of the risk factors for MAEs was not feasible owing to the small number of events.

On the other hand, it is believed that this is the first observational clinical study describing the clinical outcomes of an off the shelf thoraco-abdominal device in the specific anatomical setting of JP-AAA, thus setting a benchmark for future comparisons.

## Conclusion

In this real life non-sponsored registry, the E-nside endograft was used for the treatment of JP-AAA in both elective and urgent settings. E-nside use was feasible, with high technical success, although longer follow up data are still required. A satisfactory freedom from target vessel instability was observed at one year. Stroke and SCI may be associated with upper limb access and the increased aortic coverage that the device design brings. Alternative endovascular options and technical choices, allowing for shorter coverage of the thoracic aorta and a total transfemoral approach, should be considered for the treatment of JP-AAAs.

## CONFLICTS OF INTEREST

F.S.: consulting agreement with Medtronic and Gore; all consulting fees paid to the Department of Cardiac, Thoracic, Vascular Sciences and Public Health, University of Padua; M.P.: consulting agreement with Artivion, Medtronic, Gore,

and Cook; all consulting fees paid to the Department of Cardiac, Thoracic, Vascular Sciences and Public Health, University of Padua; G.I.: consulting agreement with Artivion, BD UK Ltd, Kawasumi lab, Shockwave Inc, Cordis, and Penumbra; G.P.: consulting agreement with Medtronic, Cook, and Artivion; M.A.: consulting agreement with Artivion, Medtronic, Gore, Siemens, and Lombard; all consulting fees paid to the Department of Cardiac, Thoracic, Vascular Sciences and Public Health, University of Padua.

## APPENDIX A. SUPPLEMENTARY DATA

Supplementary data to this article can be found online at <https://doi.org/10.1016/j.ejvs.2025.02.030>.

## REFERENCES

- 1 Wanhainen A, Van Herzele I, Bastos Goncalves F, Bellmunt Montoya S, Berard X, Boyle JR, et al. Editor's Choice – European Society for Vascular Surgery (ESVS) 2024 clinical practice guidelines on the management of abdominal aorto-iliac artery aneurysms. *Eur J Vasc Endovasc Surg* 2024;**67**:192–331.
- 2 Oderich GS, Forbes TL, Chaer R, Davies MG, Lindsay TF, Mastracci T, et al. Reporting standards for endovascular aortic repair of aneurysms involving the renal-mesenteric arteries. *J Vasc Surg* 2021;**73**(1S):4S–52S.
- 3 Piazza M, Squizzato F, Pratesi G, Tshomba Y, Gaggiano A, Gatta E, et al. Editor's Choice – Early outcomes of a novel off the shelf preloaded inner branch endograft for the treatment of complex aortic pathologies in the ItaliaN Branched Registry of E-nside EnDograft (INBREED). *Eur J Vasc Endovasc Surg* 2023;**65**:811–17.
- 4 Bosiers M, Kölbel T, Resch T, Tsilimparis N, Torsello G, Austermann M. Early and midterm results from a postmarket observational study of Zenith t-Branch thoracoabdominal endovascular graft. *J Vasc Surg* 2021;**74**:1081–9.e3.
- 5 Spanos K, Kölbel T, Theodorakopoulou M, Heidemann F, Rohlffs F, Debus ES, et al. Early outcomes of the t-Branch off-the-shelf multibranch stent-graft in urgent thoracoabdominal aortic aneurysm repair. *J Endovasc Ther* 2018;**25**:31–9.
- 6 Kölbel T, Spanos K, Jama K, Behrendt C-A, Panuccio G, Eleshra A, et al. Early outcomes of the t-Branch off-the-shelf multi-branched stent graft in 542 patients for elective and urgent aortic pathologies: a retrospective observational study. *J Vasc Surg* 2021;**74**:1817–24.
- 7 Mastracci TM, Eagleton MJ, Kuramochi Y, Bathurst S, Wolski K. Twelve-year results of fenestrated endografts for juxtarenal and group IV thoracoabdominal aneurysms. *J Vasc Surg* 2015;**61**:355–64.
- 8 Spath P, Tsilimparis N, Furlan F, Hamwi T, Prendes CF, Stana J. Additional aortic coverage with an off the shelf, multibranch endograft compared with custom made devices for endovascular repair of pararenal abdominal aortic aneurysms. *Eur J Vasc Endovasc Surg* 2023;**65**:710–18.
- 9 Piazza M, Squizzato F, Forcella E, Bilato MJ, Colacchio EC, Grego F, et al. Effect of narrow paravisceral aorta on target vessel instability after fenestrated and branched endovascular aortic repair. *J Vasc Surg* 2024;**79**:217–27.e1.
- 10 Harris PA, Taylor R, Thielke R, Payne J, Gonzalez N, Conde JG. Research electronic data capture (REDCap): a metadata-driven methodology and workflow process for providing translational research informatics support. *J Biomed Inform* 2009;**42**:377–81.
- 11 Thygesen K, Alpert JS, Jaffe AS, Chaitman BR, Bax JJ, Morrow DA, et al. Fourth universal definition of myocardial infarction (2018). *Circulation* 2018;**138**:e618–51.
- 12 Sharma V, Rao V, Manlhiot C, Boruvka A, Fremes S, Wąsowicz M. A derived and validated score to predict prolonged mechanical ventilation in patients undergoing cardiac surgery. *J Thorac Cardiovasc Surg* 2017;**153**:108–15.
- 13 Squizzato F, Antonello M, Modena M, Forcella E, Colacchio EC, Grego F, et al. Fate of primary determinate and indeterminate target vessel endoleaks after fenestrated-branched endovascular aortic repair. *J Vasc Surg* 2024;**79**:207–16.e4.
- 14 Zimmermann A, Menges A-L, Rancic Z, Meuli L, Dueppers P, Reutersberg B. E-nside off-the-shelf inner branch stent graft: technical aspects of planning and implantation. *J Endovasc Ther* 2022;**29**:167–74.
- 15 Piazza M, Pratesi G, Tshomba Y, Gaggiano A, Carbonari L, Simonte G, et al. Early outcomes of a novel off-the-shelf preloaded inner branch endograft for the treatment of complex aortic pathologies in the ItaliaN Branched Registry of E-nside EnDograft (INBREED). *J Vasc Surg* 2022;**75**:e332–3.
- 16 Matthay MA, Arabi Y, Arroliga AC, Bernard G, Bersten AD, Brochard LJ, et al. A new global definition of acute respiratory distress syndrome. *Am J Respir Crit Care Med* 2024;**209**:37–47.
- 17 Squizzato F, Oderich GS, Balachandran P, Tenorio ER, Mendes BC, De Martino RR. Effect of aortic angulation on the outcomes of fenestrated-branched endovascular aortic repair. *J Vasc Surg* 2021;**74**:372–82.e3.
- 18 Tsilimparis N, Fiorucci B, Debus ES, Rohlffs F, Kölbel T. Technical aspects of implanting the t-Branch off-the-shelf multibranch stent-graft for thoracoabdominal aneurysms. *J Endovasc Ther* 2017;**24**:397–404.
- 19 Bilman V, Cambiaghi T, Grandi A, Carta N, Melissano G, Chiesa R, et al. Anatomical feasibility of a new off-the-shelf inner branch stent graft (E-nside) for endovascular treatment of thoraco-abdominal aneurysms. *Eur J Cardiothorac Surg* 2020;**58**:1296–303.
- 20 Bertoglio L, Grandi A, Carta N, Cambiaghi T, Bilman V, Melissano G, et al. Comparison of anatomic feasibility of three different multibranch off-the-shelf stent-grafts designed for thoracoabdominal aortic aneurysms. *J Vasc Surg* 2021;**74**:1472–82.e4.
- 21 Bertoglio L, Cambiaghi T, Ferrer C, Baccellieri D, Verzini F, Melissano G, et al. Comparison of sacrificed healthy aorta during thoracoabdominal aortic aneurysm repair using off-the-shelf endovascular branched devices and open surgery. *J Vasc Surg* 2018;**67**:695–702.
- 22 Georgiadis GS, van Herwaarden JA, Antoniou GA, Hazenberg CEVB, Giannoukas AD, Lazarides MK, et al. Systematic review of off-the-shelf or physician-modified fenestrated and branched endografts. *J Endovasc Ther* 2016;**23**:98–109.
- 23 O'Donnell TFX, Boitano LT, Deery SE, Schermerhorn ML, Schanzer A, Beck AW, et al. Open versus fenestrated endovascular repair of complex abdominal aortic aneurysms. *Ann Surg* 2020;**271**:969–77.
- 24 Zlatanovic P, Mascia D, Ancetti S, Yeung KK, Graumans MJ, Jongkind V, et al. Short term and long term clinical outcomes of endovascular versus open repair for juxtarenal and pararenal abdominal aortic aneurysms using propensity score matching: results from Juxta- and Pararenal Aortic Aneurysm Multicentre European Study (JAMES). *Eur J Vasc Endovasc Surg* 2023;**65**:828–36.
- 25 Chamseddin K, Timaran CH, Oderich GS, Tenorio ER, Farber MA, Parodi FE, et al. Comparison of upper extremity and transfemoral access for fenestrated-branched endovascular aortic repair. *J Vasc Surg* 2023;**77**:704–11.
- 26 Katsargyris A, Marques de Marino P, Mufty H, Pedro LM, Fernandes R, Verhoeven ELG. Early experience with the use of inner branches in endovascular repair of complex abdominal and thoraco-abdominal aortic aneurysms. *Eur J Vasc Endovasc Surg* 2018;**55**:640–6.
- 27 Piazza M, Squizzato F, Pratesi G, Parlani G, Simonte G, Giudice R, et al. Outcomes of off the shelf outer branched versus inner branched endografts in the treatment of thoraco-abdominal aortic aneurysm in the B.R.I.O. (BRanched Inner – Outer) study group. *Eur J Vasc Endovasc Surg* 2024;**80**:1350–60.e4.
- 28 Piazza M, Squizzato F, Ferri M, Pratesi G, Gatta E, Orrico M, et al. Outcomes of off-the-shelf preloaded inner branch device for urgent endovascular thoraco-abdominal aortic repair in the ItaliaN Branched Registry of E-nside EnDograft. *J Vasc Surg* 2024;**80**:1350–60.e4.

- 29 Tenorio ER, Schanzer A, Timaran CH, Schneider DB, Mendes BC, Eagleton MJ, et al. Effect of bridging stent graft selection for directional branches on target artery outcomes of fenestrated-branched endovascular aortic repair in the United States Aortic Research Consortium. *J Vasc Surg* 2023;**78**:10–28.e3.
- 30 Tenorio ER, Kärkkäinen JM, Mendes BC, DeMartino RR, Macedo TA, Diderrich A, et al. Outcomes of directional branches using self-expandable or balloon-expandable stent grafts during endovascular repair of thoracoabdominal aortic aneurysms. *J Vasc Surg* 2020;**71**:1489–502.e6.
- 31 Gallitto E, Faggioli G, Spath P, Pini R, Mascoli C, Ancetti S, et al. The risk of aneurysm rupture and target visceral vessel occlusion during the lead period of custom-made fenestrated/branched endograft. *J Vasc Surg* 2020;**72**:16–24.
- 32 Konstantinou N, Antonopoulos CN, Jerkku T, Banafsche R, Kölbl T, Fiorucci B, et al. Systematic review and meta-analysis of published studies on endovascular repair of thoracoabdominal aortic aneurysms with the t-Branch off-the-shelf multibranched endograft. *J Vasc Surg* 2020;**72**:716–25.e1.
- 33 Ferrer C, Orrico M, Spataro C, Coscarella C, Ronchey S, Marino M, et al. Outcomes of multibranched off-the-shelf stent graft in elective and urgent/emergent repair of complex aortic aneurysms with narrow internal aortic lumen. *J Vasc Surg* 2022;**76**:326–34.
- 34 Ferreira M, Mannarino M, Cunha R, Ferreira D, Capotorto LF, Oderich GS. Stent graft modification to preserve intercostal arteries using thoracoabdominal off-the-shelf multibranched (t-Branch) endograft. *J Endovasc Ther* 2021;**28**:382–7.
- 35 Gallitto E, Faggioli G, Austermann M, Kölbl T, Tsilimparis N, Dias N, et al. Urgent endovascular repair of juxtarenal/pararenal aneurysm by off-the-shelf multibranched endograft. *J Vasc Surg* 2024;**80**:1336–49.e4.
- 36 Oderich GS, Farber MA, Silveira PG, Tadros R, Marin M, Fillinger M, et al. Technical aspects and 30-day outcomes of the prospective early feasibility study of the GORE EXCLUDER Thoracoabdominal Branched Endoprosthesis (TAMBE) to treat pararenal and extent IV thoracoabdominal aortic aneurysms. *J Vasc Surg* 2019;**70**:358–68.e6.
- 37 Piazza M, Squizzato F, Spertino A, Grego F, Antonello M. Standardized approach for four-fenestrated physician-modified endograft to treat complex abdominal aortic aneurysms using Valiant Captivia. *J Vasc Surg Cases Innov Tech* 2024;**10**:101491.
- 38 Chait J, Tenorio ER, Hofer JM, DeMartino RR, Oderich GS, Mendes BC. Five-year outcomes of physician-modified endografts for repair of complex abdominal and thoracoabdominal aortic aneurysms. *J Vasc Surg* 2023;**77**:374–85.e4.
- 39 Canonge J, Jayet J, Heim F, Chakfé N, Coggia M, Coscas R, et al. Comprehensive review of physician modified aortic stent grafts: technical and clinical outcomes. *Eur J Vasc Endovasc Surg* 2021;**61**:560–9.
- 40 Squizzato F, Piazza M, Forcella E, Coppadoro S, Grego F, Antonello M. Clinical impact and determinants of fenestration to target vessel misalignment in fenestrated endovascular aortic repair. *Eur J Vasc Endovasc Surg* 2023;**67**:765–74.
- 41 Squizzato F, Antonello M, Forcella E, Coppadoro S, Colacchio C, Xodo A, et al. Geometrical determinants of target vessel instability in fenestrated endovascular aortic repair. *J Vasc Surg* 2022;**76**:335–43.e2.
- 42 Ferreira M, Mannarino M, Cunha R, Ferreira D, Capotorto LF. Urgent juxtarenal aortic aneurysm repair with modified off-the-shelf endograft to preserve intercostal arteries and branch incorporation by transfemoral access. *J Endovasc Ther* 2023; doi: 10.1177/15266028231199042 [epub ahead of print].
- 43 Vallabhaneni SR, Patel SR, Campbell B, Boyle JR, Cook A, Crosher A, et al. Editor's Choice – Comparison of open surgery and endovascular techniques for juxtarenal and complex neck aortic aneurysms: the UK COMpLex Aneurysm Study (UK-COMPASS): peri-operative and midterm outcomes. *Eur J Vasc Endovasc Surg* 2024;**67**:540–53.