

## Case Report

Prostate and male voiding dysfunctions

pISSN: 2287-4208 / eISSN: 2287-4690  
World J Mens Health Published online Jul 18, 2023  
<https://doi.org/10.5534/wjmh.220272>

The World Journal of  
**MEN'S HEALTH**



# Does SARS-CoV-2 Affect the Prostate? A Molecular Analysis from a Case Series of COVID-19 Patients

Sara Stigliani<sup>1</sup>, Claudia Massarotti<sup>2</sup>, Simona Coco<sup>3</sup>, Guglielmo Mantica<sup>4</sup>, Nataniele Pioi<sup>5</sup>, Bruno Spina<sup>5</sup>, Elena Maccarini<sup>1</sup>, Monica Colombo<sup>5,6</sup>, Paola Anserini<sup>1</sup>, Paola Scaruffi<sup>1</sup>

<sup>1</sup>UOS Physiopathology of Human Reproduction, IRCCS Ospedale Policlinico San Martino, <sup>2</sup>Department of Neuroscience, Rehabilitation, Ophthalmology, Genetics and Maternal-Child Health (DiNOGMI), University of Genova, <sup>3</sup>Unit of Lung Cancer, IRCCS Ospedale Policlinico San Martino, <sup>4</sup>Department of Urology, IRCCS Ospedale Policlinico San Martino, <sup>5</sup>Unit of Patology, IRCCS Ospedale Policlinico San Martino, <sup>6</sup>Molecular Pathology Unit, IRCCS Ospedale Policlinico San Martino, Genova, Italy

Severe acute respiratory syndrome Coronavirus 2 (SARS-CoV-2) causes COVID-19 that has been spreading worldwide since December 2019. Viral entry into cells requires expression of both angiotensin-converting enzyme 2 (ACE2) and transmembrane protease serine 2 (TMPRSS2) on the surface of the host cell. The male reproductive system, including the prostate, was supposed to be a potential target for SARS-CoV-2 since the presence of ACE and TMPRSS2 receptors. This paper investigated for the first time the presence of SARS-CoV-2 mRNA in the prostatic tissue of a patient with active infection. In addition, we searched for the virus in the prostate of five patients after their recovery from COVID-19. The SARS-CoV-2 RNA was not detected in any of the prostate tissues tested even during the acute phase of infection. As case series have limitations, causality cannot be excluded and sporadic evidence of prostatic tissue invasion by SARS-CoV-2 may be detectable.

**Keywords:** COVID-19; Genitalia, male; Prostate; Real-time polymerase chain reaction; SARS-CoV-2

This is an Open Access article distributed under the terms of the Creative Commons Attribution Non-Commercial License (<http://creativecommons.org/licenses/by-nc/4.0>) which permits unrestricted non-commercial use, distribution, and reproduction in any medium, provided the original work is properly cited.

Severe acute respiratory syndrome Coronavirus 2 (SARS-CoV-2) is a single-stranded RNA coronavirus and it causes Coronavirus disease 2019 (COVID-19). The SARS-CoV-2 consists of a nucleoprotein surrounding the RNA genome, a viral envelope, and a spike protein, which plays a crucial role in attachment and fusion with the cell during infection [1]. Viral entry into cells requires expression of both angiotensin-converting enzyme 2 (ACE2) and transmembrane protease serine 2 (TMPRSS2) on the surface of the host cell [1].

The ACE2 and TMPRSS2 are widely expressed in the lungs and other human tissues, including prostate

epithelial cells. Given this finding, it was reasonable to hypothesize that the prostate may be susceptible to SARS-CoV-2 infection [2]. However, with the exception of two studies that identified SARS-CoV-2 in prostatic tissue [3,4], all other studies on this topic reported the absence of SARS-CoV-2 in prostatic secretion from patients suffering from COVID-19 [5,6] as well as in prostate tissue of one patient with resolving infection [7].

To answer the unmet question whether the virus was actually present in the prostate during COVID-19, we investigated the presence of SARS-CoV-2 mRNA in the prostatic tissue of a patient during infection. In

**Received:** Dec 15, 2022 **Revised:** Mar 20, 2023 **Accepted:** Apr 9, 2023 **Published online** Jul 18, 2023

**Correspondence to:** Paola Scaruffi <https://orcid.org/0000-0001-9799-1661>

UOS Physiopathology of Human Reproduction, IRCCS Ospedale Policlinico San Martino, Largo R. Benzi, 10, Genova 16132, Italy.

**Tel:** +39-010-5555847, **Fax:** +39-010-5556909, **E-mail:** [paola.scaruffi@hsanmartino.it](mailto:paola.scaruffi@hsanmartino.it)

addition, we searched for the virus in prostate of five patients after recovery from COVID-19. As far as we know, it is the cohort with the longest follow-up so far.

### CASE REPORT

After approval by the Ethics Committee of Regione Liguria (no. 12610/2022), six males who underwent transvesical prostatic adenomectomy or thulium laser enucleation of the prostate (ThuLEP) or transurethral resection of the prostate (TURP) due to benign prostate hypertrophy (BPH)/adenoma were included in the study. The characteristics of patients are detailed in Table 1. One patient (#1) had ThuLEP during COVID-19 disease (one day after the positive nasopharyngeal swab for SARS-CoV-2 infection), while the others had prostate surgery after a median time 8.0 months (1–12.0 months) from recovery. All patients had severe symptoms of COVID-19 with associated pneumonia that required hospitalization in four of the six cases. The median age at the time of COVID-19 disease was 74.0 years (59.0–85.0 years).

Microscope evaluation of prostatic tissue showed no lesions related to virus infection. RNA was purified from two 10 µm thick sections by the RNeasy® FFPE kit (Qiagen) and quantified by Qubit™ RNA High Sensitivity kit in Qubit Fluorometer (Thermo Fisher Scientific). Each sample (200 ng) was simultaneously tested for the following targets: human RNA target (*RNase P*, internal control), Nucleocapsid (*N*) gene and Open Reading Frame 1ab (*ORF1ab*) gene by SARS-CoV-2 reverse transcriptase qPCR Reagent Kit (PerkinElmer Genomics) on the CFX96 qPCR Real-Time System (BioRad Laboratories).

As it is shown in Fig. 1, the SARS-CoV-2 RNA was

not detected in any of the samples tested with a sensitivity and specificity of 100% and 99%, respectively and a limit of detection of 20 copies for each virus target, as specified by the manufacturer's instructions.

Most patients had moderate to severe symptoms of lower urinary tract.

In 5 patients serum levels of prostate specific antigen (PSA) measured before diagnosis of COVID-19 infection and after COVID-19 recovery, but prior to prostate surgery, were available and retrospectively compared by paired samples t-test. Average PSA levels were 5.7+2.4 µg/L in the pre-COVID-19 period and 7.6+1.2 µg/L in the post-COVID-19 period, with no significant difference (p=0.159) (Fig. 2). In one patient we had the opportunity to evaluate PSA levels in the pre-COVID-19 (3.9 µg/L), active infection (86.2 µg/L) and post-COVID-19 (7.2 µg/L) periods, showing that in the active period of the disease the level of PSA was higher than levels measured before and after infection.

### DISCUSSION

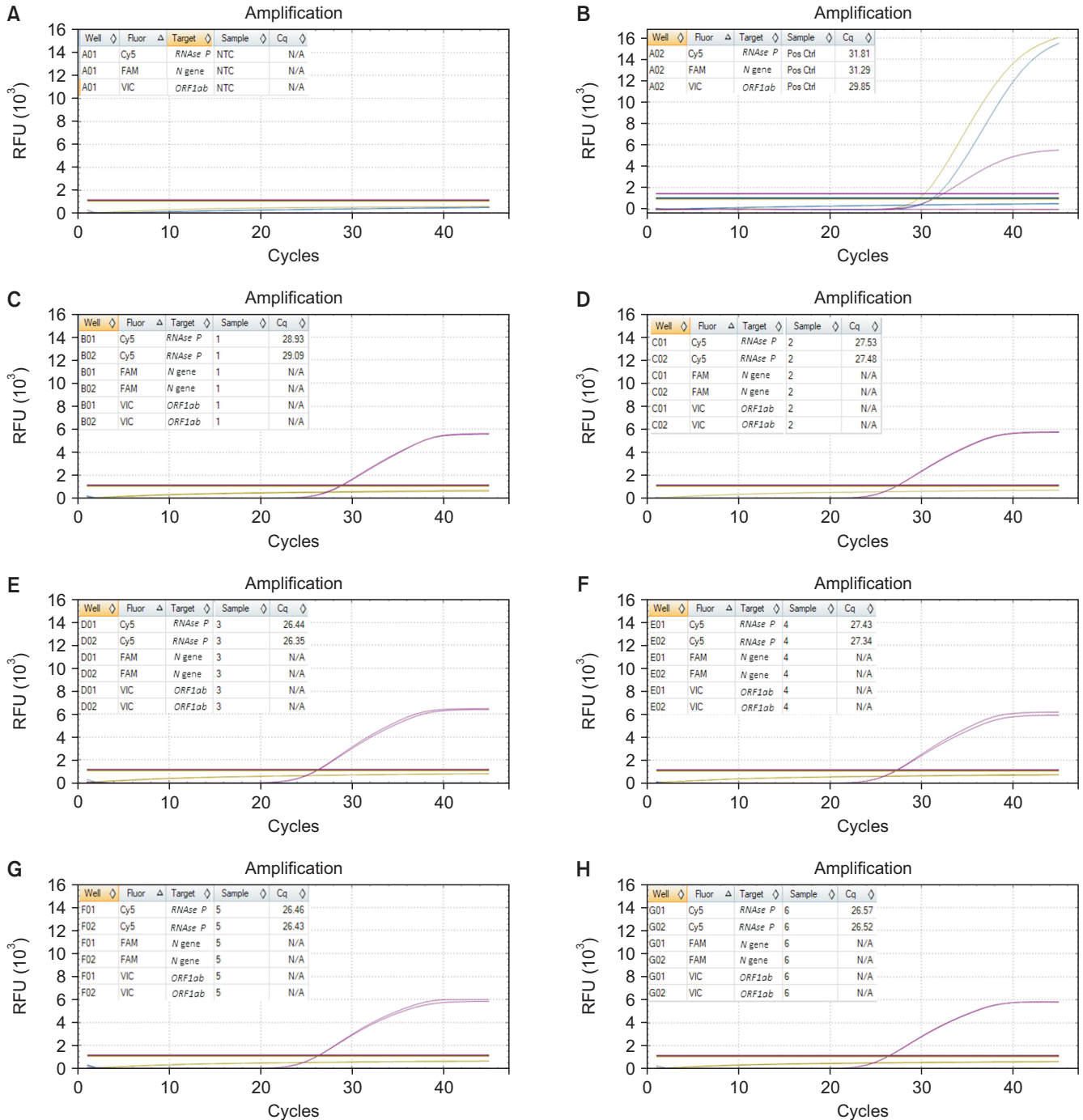
Our study, conducted in a cohort of patients with severe symptoms of COVID-19, reveals no evidence of the virus in prostate tissue either in patients with ongoing infection or who have just recovered several months.

Our findings agree with Cito et al [7] who reported that neither histopathological nor microbiology examinations detected the presence of residual SARS-CoV-2 in the prostate tissue of a patient during the resolution phase. In this regard, no severe structural histopathological damage of the prostate was observed during infection and microthrombi observed in the prostate after a fatal COVID-19 infection could be the consequence of a multi-organ failure. In addition, in

Table 1. Demographic and clinical characteristics of patients

ID	Age (yr)	Symptoms of COVID-19	Type of prostate disease	Type of prostate surgery	Interval time from COVID-19 and surgery (mo)
#1	59	Pneumonia, hospitalization+ mild symptoms	Prostate adenoma	ThuLEP	5+0
#2	85	Pneumonia	Prostate adenoma	ThuLEP	1
#3	68	Pneumonia, hospitalization	Prostate adenoma	TURP	9
#4	73	Pneumonia	Prostatic hypertrophy	Transvesical adenomectomy	8
#5	75	Pneumonia, hospitalization	Prostatic hypertrophy	ThuLEP	5
#6	77	Pneumonia, hospitalization in intensive care	Prostatic hypertrophy	ThuLEP	12

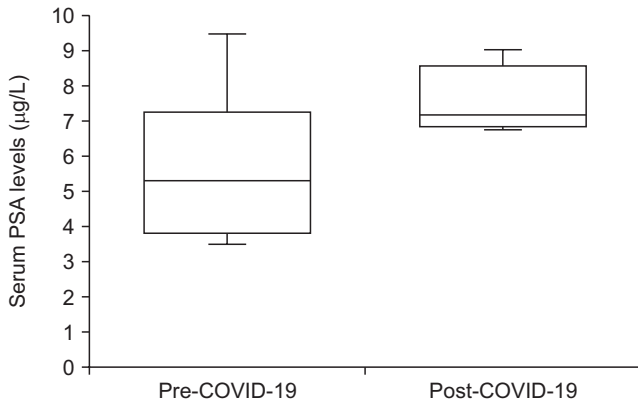
ThuLEP: thulium laser enucleation of the prostate, TURP: transurethral resection of the prostate.



**Fig. 1.** Graphical representation of real-time quantitative polymerase chain reaction (qPCR) data in negative control (nuclease-free water) (A), positive control (a plasmid containing SARS-CoV-2 target sequences) (B), and prostate samples #1 to #6 (C–H). In each panel the relative fluorescence units (RFUs) levels for qPCR reactions are plotted against the PCR cycle number. For controls and all samples, the quantification cycles (Cq) for the three target genes run in duplicate are shown. In plots the yellow line refers to *ORF1ab*, the red line to *N gene*, and the pink line to *RNase P*. The negative and positive controls were valid and acceptable: in negative control the Cq for each target was undetermined; in positive control  $Cq_{N}$ ,  $Cq_{ORF1ab}$ ,  $Cq_{RNase P}$  were  $<32$ . The SARS-CoV-2 RNA was not detected in any of the samples tested (C–H):  $Cq_{N}$  and  $Cq_{ORF1ab}$  were undetermined,  $Cq_{RNase P}$  was  $<27$ .

line with our data, SARS-CoV-2 RNA was not detected in the expressed prostatic secretion of ten recovered COVID-19 male patients and sexual transmission of COVID-19 was possibly excluded [5]. On the other hand,

some authors have previously observed the opposite result: Reddy et al [3] confirmed the presence of the virus by RT-PCR, immunofluorescence and immunohistochemistry in a patient's prostate tissue, and El-



**Fig. 2.** Box-and-whisker plot showing the PSA values before (pre-COVID-19) and after (post-COVID-19) COVID-19 disease. PSA: prostate specific antigen.

saqa et al [4] performed a diagnostic test based on RT-PCR in 14 cases and successfully identified the SARS-CoV-2 genome in the prostate of one patient. The latter patient had a mild COVID-19 infection, but he had positive SARS-CoV-2 tests for 40 days. This prolonged presence of the virus may be the reason for a particular dynamic of the SARS-CoV-2 virus that allowed it to localize in other areas of the body such as the prostate. In general, case series have limitations, causality cannot be excluded and may explain sporadic evidence of SARS-CoV-2 invasion of prostatic tissue and its persistence even beyond the initial period of infection, as previously reported [3].

Another topic still being debated is PSA in COVID-19 patients. Cinislioglu et al [8] found that SARS-CoV-2 infection in men diagnosed with BPH caused significant increases in PSA levels during the active period of the disease. The authors provided as an explanation that SARS-COV-2 induces tissue damage in the prostate and down-regulation of ACE2. Since ACE-2 is an enzyme that has anti-inflammatory, anti-fibrotic and vasodilator effects by modulating the proliferative and inflammatory effects of angiotensin II, the suppression of ACE2 in SARS-CoV-2 infection could activate pro-inflammatory pathways, cause inflammation in putative sensitive organs including the prostate. Of opposite opinion are other authors [2,6,9] who concluded that the prostate may not be an organ susceptible to SARS-CoV-2 infection. Our patients showed comparable levels of PSA before and after COVID-19 disease, but we could not completely rule out a rise of PSA during the acute phase of infection, as observed in the only patient in our cohort where PSA could be dosed during

COVID-19 disease.

Most patients included in this study were diagnosed with moderate to severe lower urinary tract symptoms (LUTS), some of them presented with acute urinary retention. We have not investigated the possible role of COVID-19 in worsening BPH and progression of LUTS, and no patient questionnaire has been used to monitor the pre- and post- infection symptoms. Therefore, we cannot completely rule out an aggravation of previously diagnosed BPH, even if the microscope evaluation did not show lesions related to virus infection in the prostate tissue of the 6 patients, and we found no increase in serum PSA levels after SARS-CoV-2 infection.

Different views, even contradictory, on the ability of SARS-CoV-2 to cross the blood-testis barrier and the exact impact of SARS-CoV-2 infection on seminal parameters in infected males are still questionable. Systematic reviews concluded that the likelihood of SARS-CoV-2 being present in semen of COVID-19 patients is very low and the semen parameters do not reflect any causal harmful effect of COVID-19 disease, at least in the long term [10]. We are aware that some limitations should be considered, although we used an *in vitro* diagnostic test to detect SARS-CoV-2 RNA with a manufacturer's declaration of 100% sensitivity and 99% specificity and a detection limit of 20 copies for each virus target. First, it would be prudent to consider that we may have false negative results since we analyzed two sections of prostate tissue for each patient, which may not be representative of the entire organ. RNA tests in repetition are necessary in the future to confirm the true negative. Secondly, the small number of patients included, so future studies with a larger sample size are needed to determine the clinical significance of SARS-CoV-2 prostatic invasion. Third, no semen sampling: a study with both prostatic secretion and seminal fluid analysis would be required to confirm the absence of SARS-CoV-2.

In conclusion, the SARS-CoV-2 RNA was not detected in any of the prostate tissues tested even during the acute phase of infection, but causality cannot be excluded and sporadic evidence of prostatic tissue invasion by SARS-CoV-2 may be detectable.

Although it has been almost 3 years since the beginning of the COVID-19 pandemic, there are still many unanswered questions about this disease. After all, in the process of understanding something new like

studying the effects of SARS-CoV-2 in humans, different opinions are allowed and the above contradictory data on the male genitourinary system are a perfect example. We hope that this case series report could be a further piece of information for a thorough knowledge of SARS-CoV-2 infection.

### Conflict of Interest

The authors have nothing to disclose.

### Funding

None.

### Acknowledgements

None.

### Author Contribution

Conceptualization: SS, CM, PS. Data curation: SS, GM, NP, BS, EM. Formal analysis: SS. Investigation: SS. Methodology: SS, SC, MC. Supervision: PA. Visualization: SS, PS. Writing - original draft: PS. Writing - review & editing: SS, CM, PA, PS.

### REFERENCES

1. Letko M, Marzi A, Munster V. Functional assessment of cell entry and receptor usage for SARS-CoV-2 and other lineage B betacoronaviruses. *Nat Microbiol* 2020;5:562-9.
2. Song H, Seddighzadeh B, Cooperberg MR, Huang FW. Expression of ACE2, the SARS-CoV-2 receptor, and TMPRSS2

- in prostate epithelial cells. *Eur Urol* 2020;78:296-8.
3. Reddy R, Farber N, Kresch E, Seetharam D, Diaz P, Ramasamy R. SARS-CoV-2 in the prostate: immunohistochemical and ultrastructural studies. *World J Mens Health* 2022;40:340-3.
4. Elsaqa M, Rao A, Liu L, Hua Y, Volz M, Morris R, et al. Molecular detection of the COVID-19 genome in prostatic tissue of patients with previous infection. *Proc (Bayl Univ Med Cent)* 2022;35:759-61.
5. Zhang S, Wang X, Zhang H, Xu A, Fei G, Jiang X, et al. The absence of coronavirus in expressed prostatic secretion in COVID-19 patients in Wuhan city. *Reprod Toxicol* 2020;96:90-4.
6. Ruan Y, Hu B, Liu Z, Liu K, Jiang H, Li H, et al. No detection of SARS-CoV-2 from urine, expressed prostatic secretions, and semen in 74 recovered COVID-19 male patients: a perspective and urogenital evaluation. *Andrology* 2021;9:99-106.
7. Cito G, Di Maida F, Nesi G, Santi R, Pollini S, Rossolini GM, et al. Does SARS-CoV-2 really affect the prostate? Pathological and molecular analysis from a COVID-19 recovered patient treated with holmium laser enucleation of the prostate. *Urologia* 2022;89:311-2.
8. Cinislioglu AE, Demirdogen SO, Cinislioglu N, Altay MS, Sam E, Akkas F, et al. Variation of serum PSA levels in COVID-19 infected male patients with benign prostatic hyperplasia (BPH): a prospective cohort study. *Urology* 2022;159:16-21.
9. Di Vincenzo A, Busetto L, Vettor R, Rossato M. Prostate specific antigen in COVID-19 patients. *Andrology* 2021;9:1042.
10. He Y, Wang J, Ren J, Zhao Y, Chen J, Chen X. Effect of COVID-19 on male reproductive system - a systematic review. *Front Endocrinol (Lausanne)* 2021;12:677701.