



## Management of Stent Underexpansion and Aorto-ostial Lesions

Luca Paolucci , Asad Shabbir , Marco Lombardi , Adrián Jerónimo, Javier Escaned  and Nieves Gonzalo 

Hospital Clínico San Carlos, Universidad Complutense de Madrid, Spain

### Abstract

Stent underexpansion (SU) and aorto-ostial lesions (AOL) are challenging conditions commonly faced during clinical practice in the setting of percutaneous coronary interventions. Compared to other interventional settings, both SU and AOL are associated with an increased risk of immediate and late events following percutaneous coronary intervention. Several specific strategies including the systematic use of intracoronary imaging and dedicated techniques for lesions' preparation and calcium debulking have been described. This narrative review summarises the currently available options for the diagnosis and treatment of both SU and AOL, highlighting the potential benefits and limits of each technique in these specific settings.

### Keywords

Coronary artery disease, percutaneous coronary intervention

**Received:** 19 May 2024 **Accepted:** 10 October 2024 **Citation:** *Interventional Cardiology* 2024;19:e26. **DOI:** <https://doi.org/10.15420/icr.2024.10>

**Disclosure:** The authors have no conflicts of interest to declare.

**Correspondence:** Nieves Gonzalo, Interventional Cardiology Unit, Hospital Clínico San Carlos IdISSC, Calle del Profesor Martín Lagos, 28040, Madrid, Spain.  
E: [nieves\\_gonzalo@yahoo.es](mailto:nieves_gonzalo@yahoo.es)

**Copyright:** © The Author(s) 2024. This work is open access and is licensed under CC-BY-NC 4.0. Users may copy, redistribute and make derivative works for non-commercial purposes, provided the original work is cited correctly.

Stent underexpansion (SU) and aorto-ostial lesions (AOL) are challenging lesion subsets commonly faced during percutaneous coronary intervention (PCI). When confronted simultaneously, these can lead to suboptimal procedural results and negatively influence clinical outcomes. Despite being two distinct entities, SU and AOL share specific features in terms of procedural management, predominately owing to the high prevalence of severe calcifications and the need for dedicated techniques to achieve an optimal result.<sup>1,2</sup> In this review, we summarise the clinical features and treatment strategies for these two conditions.

### Stent Underexpansion Definition

Robust evidence suggests that SU is one of the key determinants of restenosis and thrombosis after PCI.<sup>3,4</sup> SU is defined as the suboptimal expansion of the stent compared to the reference vessel diameter, occurring immediately after PCI. Stent expansion can be assessed using the absolute value of the minimum stent area (MSA) or the MSA in relation to the reference vessel (relative expansion, %). In *de novo* lesions, calcification length, circumferential superficial calcified deposits, nodular calcification, and small reference vessel diameter have been demonstrated to be associated with an increased risk of SU.<sup>5</sup> In the setting of in-stent restenosis (ISR), other predictors such as neointimal calcification, previous SU and multiple layers of stent have also been implicated.<sup>6</sup>

### Strategies to Avoid Stent Underexpansion

In most cases, SU is a consequence of improper lesion evaluation and preparation. The risk of SU can be significantly reduced by careful evaluation of a specific lesion's features. Several predictive models, mostly relying on intracoronary imaging, have been developed. Calcification angle >180°, length >5 mm and thickness >0.5 mm have all

been demonstrated to be associated with an increased risk of SU (Fujino score).<sup>7</sup> Beyond these, other important predictors of SU, such as reduced reference lumen area and plaque burden, have been described.<sup>8</sup> Following lesion evaluation, a specific debulking strategy should be chosen according to its features. Several algorithms to manage coronary calcifications have been proposed.<sup>9</sup> Briefly, for balloon-crossable lesions a pre-dilation with non-compliant (NC) or scoring/cutting balloons sized 1:1 with the vessel reference diameter should be attempted. In case of ineffective lesion preparation, other more advanced debulking strategies such as intravascular lithotripsy (IVL), rotational atherectomy (RA) or orbital atherectomy (OA) should be considered according to the crossability of the lesion and the deepness of the calcification. For balloon uncrossable lesions, upfront atherectomy should be considered. Before stent implantation, proper lesion preparation should be routinely confirmed. This can be achieved by evaluating the expansion of a 1:1-sized NC balloon at the lesion site (absence of 'dog bone' effect). If available, intracoronary imaging can provide further details by identifying indirect signs of effective debulking as calcium fractures.<sup>10</sup>

### Diagnosis

While angiography is limited for the evaluation of SU, it is still the standard diagnostic strategy in several cath labs due to a limited penetration of intracoronary imaging in routine clinical practice.<sup>11</sup> When relying on isolated angiography during PCI, operators should pay close attention to the expansion of the balloons in two orthogonal projections. When available, the diagnostic utility of coronary angiography can be increased substantially with dedicated stent enhancement tools such as StentBoost (Philips Medical Systems) and ClearStent (Siemens). These systems can be useful either to evaluate the morphology of previously implanted stents or to highlight the presence of calcifications which

**Table 1: Criteria for Optimal Stent Expansion in Major Randomised Studies on Imaging Guided Percutaneous Coronary Intervention**

Study	Optimal Expansion Criteria
HOME DES IVUS 2010 <sup>71</sup>	IVUS: MSA $\geq 5\text{mm}^2$ or $>90\%$ of distal reference area
AIR-CTO 2015 <sup>72</sup>	IVUS: MSA $>80\%$ of mean reference area
CTO-IVUS 2015 <sup>73</sup>	IVUS: MSA $\geq$ distal reference area of $\geq 5\text{mm}^2$
DOCTORS 2016 <sup>74</sup>	OCT: MSA $>80\%$ of mean reference area
ROBUST 2018 <sup>75</sup>	OCT: MSA $>80\%$ of mean reference area
IVUS-XPL 2015 <sup>76</sup>	IVUS: MSA $>90\%$ of distal reference area
ILUMIEN III 2016 <sup>77</sup>	OCT: MSA $>90\%$ of both proximal and distal reference areas
ULTIMATE 2018 <sup>78</sup>	IVUS: MSA $\geq 5\text{mm}^2$ or $>90\%$ of distal reference area
iSIGHT 2021 <sup>79</sup>	IVUS and OCT: MSA $>80\%$ of mean reference area
RENOVATE COMPLEX PCI 2023 <sup>80</sup>	IVUS: MSA $>5.5\text{mm}^2$ or $>80\%$ of mean reference area OCT: MSA $>4.5\text{mm}^2$ or $>80\%$ of mean reference area
ILUMIEN IV 2023 <sup>81</sup>	OCT: MSA $>90\%$ of both proximal and distal reference areas
OCTOBER 2023 <sup>82</sup>	OCT: MSA $>90\%$ of both proximal and distal reference areas
OCTIVUS 2023 <sup>83</sup>	IVUS and OCT: MSA $>80\%$ of mean reference area

DES = drug-eluting stents; IVUS = intravascular ultrasound; MSA = minimal stent area; OCT = optical coherence tomography.

could not be detected with simple fluoroscopy. Additionally, some technologies can offer the possibility of a 3D reconstruction of the implanted stent, thereby providing a quantitative evaluation of stent expansion (3Dstent, GE HealthCare).

Intracoronary imaging is the gold standard technique to diagnose SU. For this purpose, either intravascular ultrasound (IVUS) or optical coherence tomography (OCT) can be used. Despite several imaging-based definitions of SU currently available, there is no consensus on which should be preferred. Specifically, the percentage of underexpansion is expressed as a ratio between MSA and the vessel's area, which can be measured in different ways (at MSA site, as a mean absolute reference measure, as a linearly predicted value or according to the proximal/distal reference sizes).<sup>12</sup> Moreover, SU can be categorically defined using different percentage thresholds for each one of these definitions (30%, 20% or 10%, respectively).<sup>13</sup> Considering the high heterogeneity between these different definitions, it is not surprising that the incidence of this complication varies dramatically according to the used criteria, ranging between 5% and 40% of cases.<sup>12-14</sup> Similarly, while there is a consensus that this complication is associated with poor outcomes, the relationship between the different definitions and the risk of target lesion failure is variable, especially when considering the most sensitive criteria (i.e. those using low percentages cut-offs to define SU).<sup>12-14</sup>

Current consensus documents for the use of intracoronary imaging recommend using an absolute value of MSA  $<5.5\text{mm}^2$  for IVUS or  $<4.5\text{mm}^2$  for OCT to define stent underexpansion, or 80% of the MSA/average reference lumen as a relative value to define the presence of underexpansion.<sup>15</sup> The SU definitions used in major trials on imaging-guided PCI have been synthesised in *Table 1*.

## Treatment

NC balloons are commonly used as a first-line strategy to treat SU. Although these devices can be effective in improving the stent luminal area when insufficient lesion preparation has been performed, or under-sized stents have been deployed, they often fail in complex settings and

can rupture when attempting to reach higher inflation pressures.<sup>16</sup> When NC balloons fail, super high-pressure balloons (which have rated burst pressures of up to 35 atm) can be useful, yet reports on SU have described conflicting results in terms of efficacy.<sup>17,18</sup> Moreover, concerns exist regarding the risk of coronary perforation.

Scoring and cutting balloons are widely available devices, often used as a second-line treatment for complex calcific lesion preparation due to their safety and ease of use. Compared to NC balloons, these devices have been demonstrated to be effective in improving luminal diameters and final MSA.<sup>19</sup> Despite this, their utility in SU is limited and few experiences have been reported.<sup>20</sup> The presence of the stent struts can limit the contact surface between the scoring/cutting blades with the vessel lumen, as demonstrated in bench test models.<sup>21</sup> An important anatomical setting where cutting/scoring balloons can be effective is represented by highly fibrotic coronary lesion (*de novo* or restenosis related to SU). Those lesions tend to be poorly responsive to other techniques commonly used to face coronary calcifications, while they can be associated with a similar risk of major complications as coronary perforation. In such cases, these devices can be effective in increasing acute lumen gain and facilitate further interventions.<sup>22,23</sup> Moreover, when a stent-less strategy with drug-coated balloons (DCB) is planned, some evidence suggests that cutting and scoring balloons might increase anti-restenotic efficacy of those devices, probably due to an increased distribution of the antiproliferative drug secondary to the incisions caused by the scoring/cutting elements at the level of the neo-intima.<sup>24</sup>

Since the first case descriptions, there has been growing interest in the use of IVL to treat SU. To date, two different observational studies, the CRUNCH and the DRAGON registries, have supported the efficacy of IVL in increasing MSA of severely underexpanded stents, with no significant procedural complications in most cases.<sup>25,26</sup> Notably, a significant proportion (41.4%) of patients enrolled in the CRUNCH registry showed acute SU, highlighting the potential benefits of IVL-PCI as a bail-out strategy when this complication is identified immediately after stent implantation. Nevertheless, it is unclear if IVL can compromise the drug-eluting capacity of the treated stents.<sup>27</sup> To date, most of the studies have reported very limited follow-up of patients, which prevents definitive conclusions on the long-term efficacy of this strategy.<sup>28</sup> Overall, IVL for the treatment of SU should be considered as an off-label/bail-out option, until more definitive data are available.

Post-PCI RA, also called 'stent ablation', should be considered as a bail-out strategy for treating uncrossable/undilatable older stents. This technique can lead to partial or complete removal of the metallic scaffold and can facilitate further lesion-preparation and/or stent delivery.<sup>29</sup> Some concern has existed regarding the risk of distal embolisation of metallic particles and possible systemic toxicity, but studies have shown this risk to be negligible.<sup>30</sup> Rotational atherectomy (RA) has been proven to be effective in this setting, with procedural success rates  $>80\%$ .<sup>31</sup> Nevertheless, the risk of burr entrapment when performing stent ablation, especially with small burrs, is significant due to the presence of the stent struts. In addition, other complications have been reported during stent ablation such as high rates of no-reflow and vessel perforations.<sup>32</sup> Even if stent ablation seems effective in the short term, prospective studies have shown an elevated risk of lesion failure, questioning its late clinical efficacy.<sup>33</sup> Regarding OA, to date, its use for SU treatment has not been described. Considering the specific features of OA, currently its application in this setting is discouraged due to concerns related to the risk for stent deformation potentially caused by the elliptical ablating cycles, which could

lead to irreversible damage of the platform and the mandatory need for second stent implantation.

Excimer laser coronary atherectomy (ELCA) modifies plaque compliance through three distinct mechanisms: 1) photochemical, by breaking carbon-carbon bonds; 2) photothermal, by inducing cellular rupture due to thermal energy; and 3) photomechanical, by inducing air bubble formation and explosions.<sup>34</sup> Considering these several mechanisms of action, it has been hypothesised that laser atherectomy could be particularly effective in treating native coronary lesions behind the stent's struts, without damaging the device and potentially acting on the original cause of the underexpansion.<sup>35</sup> This hypothesis has led to a growing interest in its potential use for SU treatment. In the ELLEMENT registry, ELCA has been proven to be effective in this setting when combined with contrast injection instead of classical saline.<sup>36</sup> A particular subset of SU often requiring aggressive management are those lesions with two or more layers of previous stents, which represent in most cases a consequence of previous unsuccessful attempts to treat older under-expanded devices. In such cases, conventional treatment strategies often fail and stent ablation techniques can be necessary.<sup>37</sup> Overall, considering the significant risk for major complications, patients with SU not responding to balloon-based strategies and requiring more advanced treatments (either RA or ELCA) should be referred to high-volume centres with experienced operators, with available intracoronary imaging.

According to European recommendations, drug-eluting stents (DES) should be preferred over DCB for the treatment of ISR, which is a common finding in SU.<sup>38</sup> Nevertheless, compared to DES, DCB can provide sustained delivery of antiproliferative drugs without the need for permanent scaffold implantation, potentially limiting the risks associated with multiple metallic layers.<sup>39</sup> To date, head-to-head comparisons and pooled analyses comparing new-generation DES and DCB in ISR interventions have shown generally comparable efficacy in coronary interventions which have previously used bare-metal stents (BMS), however, DES might be superior to DCB when treating ISR from previous DES.<sup>40</sup> When severe SU is the most likely cause of ISR, one or more of the previously cited strategies could be necessary to effectively debulk native coronary calcifications and facilitate stent's expansion. Nevertheless, optimal results cannot always be achieved, and residual SU might still be present. In the latter case, DCB could be preferable, limiting the risk of further underexpansion of a new metallic device and allowing easier future interventions in case of recurrent ISR. Otherwise, if no residual SU is present following lesion preparation, DES implantation is feasible, using intracoronary imaging guidance to select the appropriate diameter and to limit the length of the new device.<sup>41</sup> *Figures 1 and 2* show examples of ISR associated with previously untreated SU and IVL assisted PCI in this setting.

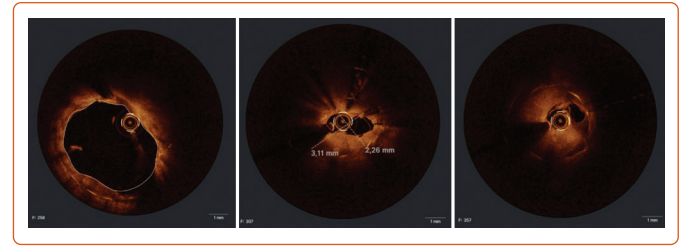
### Aorto-ostial Lesions

#### Definition

AOLs are defined as atherosclerotic plaques located in the ostial segments of native coronary vessels or surgical grafts.<sup>42</sup> AOLs are encountered in ~1.5% of unselected patients referred to coronary angiography,<sup>42</sup> but their incidence is higher in patients with known coronary artery disease or previous interventions.<sup>43</sup>

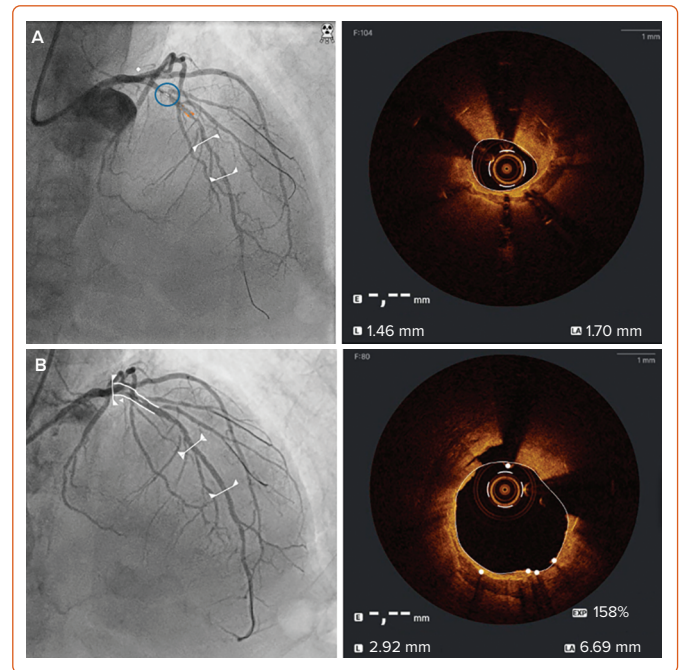
Compared to other types of lesions, AOLs present with specific anatomical and pathological features. In particular, high prevalence of intramural fibrotic degeneration extended to both intimal and medial layers and

### Figure 1: Optical Coherence Tomography Evaluation of Drug-eluting Stent In-stent Restenosis



Sequentially distal, mid and proximal segments showing significant stent underexpansion of previous device.

### Figure 2: Intracoronary Imaging in Stent Underexpansion



A: Optical coherence tomography evaluation of intrastent restenosis of proximal left anterior descending artery with severe due to stent underexpansion. B: New optical coherence tomography run after intravascular lithotripsy showing adequate stent expansion.

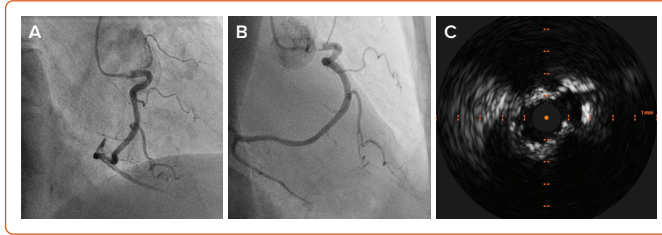
different types of complex calcifications (including isolated nodular lesions) have been documented.<sup>44,45</sup> Some of these specific properties have been attributed to the unique anatomical relationship with the aortic wall, and it has been suggested that they could be a consequence of the continuous mechanical shear stress induced by systemic pressure.<sup>46</sup>

Studies investigating the specific outcomes of AOL treated with PCI are limited. In the era of BMS, AOL were identified as an independent predictor of restenosis following PCI.<sup>47</sup> Despite the introduction of DES, the risk of stent failure has not yet been completely abolished. Contemporary evidence suggests that, compared to non-AOL, AOL could be associated with a twofold higher risk of target lesion failure and revascularisation after PCI.<sup>48</sup> Considering that most of the relevant studies referred to the BMS or early DES era, it is probable that these trends could have improved with contemporary PCI standards and the latest devices.

### Diagnosis

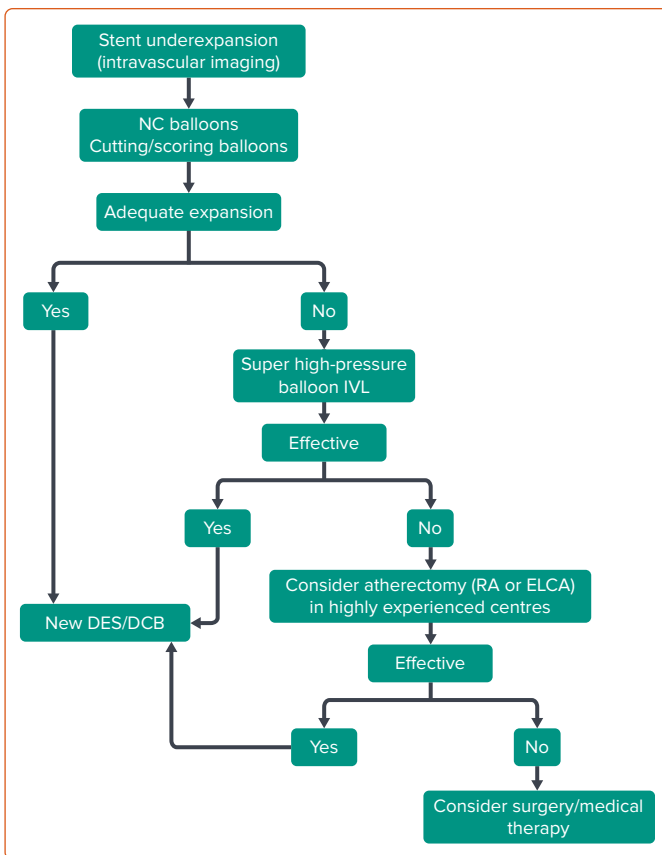
Similarly to SU, angiography can lead to suboptimal evaluation of AOL.<sup>42</sup> Occasionally, diagnostic catheters may inject contrast media distally to the lesion, hiding the presence of the stenosis. Moreover, the lack of a

Figure 3: Diagnostic Strategies for Aorto-ostial Lesions



A: 30° right anterior oblique view showing a filling defect in the proximal segment of the right coronary artery. B: 90° right anterior oblique view confirming the presence of an aorto-ostial lesion. C: Intravascular ultrasound evaluation showing the presence of severe concentric calcification previously undetected with angiography.

Figure 4: Treatment Algorithm for Stent Underexpansion



DCB = drug-coated balloon; DES = drug-eluting stent; ELCA = excimer laser coronary atherectomy; IVL = intravascular lithotripsy; NC = non-compliant; RA = rotational atherectomy.

proximal reference segment can hinder the estimation of the severity of the stenosis. Invasive pressure ventricularisation and/or damping, or the absence of backwards aortic flow, should be considered indicators of possible AOL. Catheter-induced ostial spasm is not infrequent and can generate similar findings. Effective visualisation of ostial lesions often requires non-standard projections and their proper discrimination from the aortic wall can be difficult (Figure 3A and B).<sup>49</sup>

Intracoronary imaging can be useful in evaluating the morphological features and severity of AOL (Figure 3C). IVUS has been proven to be helpful in this setting<sup>50</sup> and when evaluating left main stenosis it can even provide a direct indication for the need for coronary revascularisation due to the presence of reliable anatomical diagnostic cut-offs (safe intervention deferring for minimal areas  $\geq 6 \text{ mm}^2$ ).<sup>51</sup> In this case, operators should pay

particular attention to the coaxial position of the IVUS catheter within the coronary ostium and preferentially use guide catheters with smaller curves to avoid rotational distortion of the image. The use of OCT in AOL can be difficult owing to challenges with adequate blood clearance at the ostium.<sup>52</sup>

Physiological indices such as fractional flow reserve (FFR) and instantaneous wave-free ratio (iFR) can be used to safely infer myocardial ischaemia if special precautions are taken, including pressure equalisation in the aorta and careful intracoronary nitro-glycerine administration with coaxial guide catheter positioning.<sup>53</sup>

### Plaque Preparation in Aorto-ostial Lesions

In AOL, scoring and cutting balloons can be effective when NC balloons fail to achieve adequate expansion.<sup>54</sup> Compared to the latter, these devices provide more grip on the lesions and are less exposed to the risk of ‘melon seeding’, which is common in AOL-PCI.

Soon after its introduction RA has been recognised as a valid tool to facilitate AOL interventions.<sup>55</sup> Indeed, considering the high prevalence of severe calcification in conjunction with a lack of guide catheter support and difficulty in delivering the equipment, RA can provide an attractive alternative to facilitate PCI in this setting, especially in the right coronary artery.<sup>56</sup> Observational studies have shown that RA of AOL is associated with durable procedural results and low rates of clinical events, although outcomes are still inferior to the ones of non-AOL treated with the same strategy.<sup>57-59</sup> From a procedural perspective, there are several technical issues which might hinder effective ablation of AOL. Operators should pay close attention to the coaxial position between the catheter, which is typically not engaged in the coronary artery, and the ostium. Considering that during the first ablative runs the catheter is usually pushed back towards the aorta, proper telescopic reengagement of the guide over the burr device is usually needed. In such cases, extra-support guidewires should be preferred to increase stability.<sup>60</sup>

The use of OA for AOL is generally not recommended due to an increased risk of aortic dissection which can be caused by the elliptical rotation of the burr during the initial ablative passes.<sup>61</sup> Once OA can be delivered beyond the lesion, an alternative technique of reverse ablation has been proposed to improve procedural safety.<sup>62</sup>

IVL is an effective technique for the treatment of AOL. While ostial lesions were relatively underrepresented in the Disrupt CAD studies, larger proportions of these patients have been included in more contemporary investigations (near to 16%) with no reports of detrimental effects.<sup>63,64</sup> The use of IVL in ostial LM could raise concerns regarding the need for prolonged balloon inflations and the risk of extended periprocedural ischaemia; however, observational registries have demonstrated its safety even in this high-risk setting.<sup>65</sup>

### Stent Implantation and Drug-coated Balloons in Aorto-ostial Lesions

Stent implantation in AOL faces specific challenges, including the need for adequate coverage of the ostium, the risk of recoil and underexpansion. Proximity to the guiding catheter with the potential risk for longitudinal deformation of the stent during PCI can also hinder the treatment of this type of lesion.

Geographical miss is common when performing AOL-PCI and can be associated with an increased risk of lesion failure.<sup>66</sup> Several techniques have been developed to overcome this and enable accurate stent

implantation with adequate lesion coverage such as the use of a floating wire in the aortic sinus.

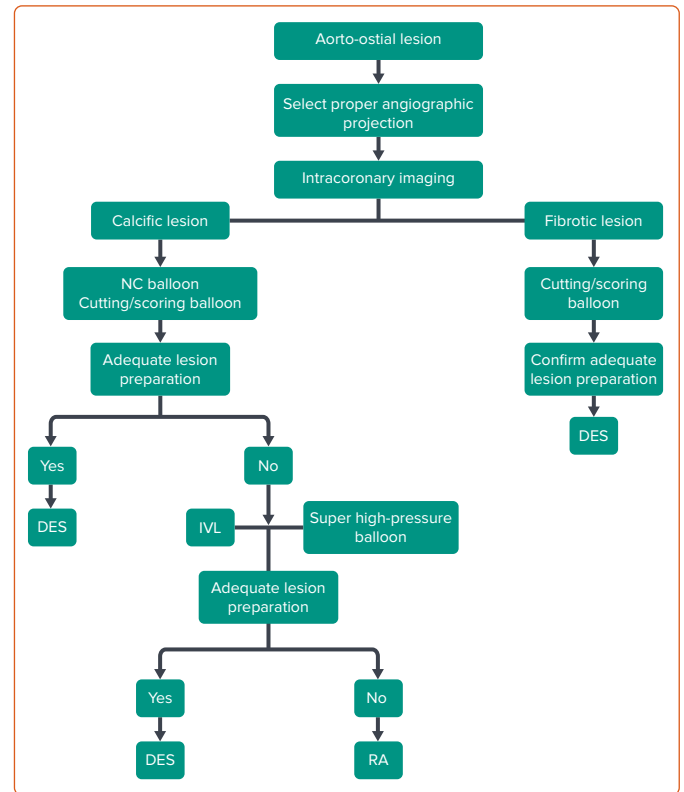
Regarding expansion, a higher risk of SU has been reported for AOL due to the presence of severe calcification or fibrotic plaques, which can induce stent recoil after implantation.<sup>67</sup> In a recently published registry reporting data from 170 AOL of the right coronary artery, >40% of lesions showed isolated calcified nodules, which have been demonstrated to be associated with higher rates of target vessel failure following revascularisation compared to non-nodular phenotypes.<sup>45</sup> Adequate plaque preparation, as previously discussed, is key to ensure adequate expansion. Some stents with higher radial force and reinforced structures that can resist longitudinal deformation have been designed to try to overcome these challenges.<sup>68</sup>

There is significant interest in the use of stent-less strategies such as DCB for the treatment of *de novo* lesions. The high rates of immediate recoil following balloon angioplasty in AOL<sup>69</sup> could limit the effectiveness of DCB and, to date, few studies have included these types of lesions.<sup>70</sup> Two randomised trials aiming to compare DCB and DES for *de novo* lesions of major coronary arteries are ongoing. Both the SELUTION *de novo* (NCT04859985) study and the TRANSFORM II (NCT04893291) study will include patients with right coronary artery ostial lesions and aim to provide relevant data.

### Conclusion

Treatment of SU and AOL represents a complex scenario in interventional cardiology, highlighting the need for dedicated strategies for calcium management, prior to deployment of stents. While adequate vessel preparation guided by intravascular imaging can be effective at preventing stent failure in these situations, impaired outcomes are still prevalent among these high-risk patients undergoing PCI. Herein, we have summarised the key techniques and considerations for the performance of PCI in SU and AOL. Two treatment algorithms for SU and AOL are proposed in *Figures 4 and 5*. However, each technique has specific benefits and limitations, and their use should be considered on an individual patient basis, depending on their anatomy.

Figure 5: Treatment Algorithm for Aorto-ostial Lesions



DES = drug-eluting stent; IVL = intravascular lithotripsy; RA = rotational atherectomy.

The lack of a universally accepted definition of SU and the systematic exclusion of AOL in several major studies has limited the generalisability of the available evidence on the long-term outcomes of PCI in these clinical scenarios. Data from future studies are highly anticipated, which may address these gaps in evidence and enable interventional cardiologists to select an optimal interventional strategy, thereby improving procedural efficacy and safety and reducing late clinical events risk. □

- Lee B, Baraki TG, Kim BG, et al. Stent expansion evaluated by optical coherence tomography and subsequent outcomes. *Sci Rep* 2023;13:3781. <https://doi.org/10.1038/s41598-023-30717-6>; PMID: 36882449.
- Alame A, Brilakis ES. Best practices for treating coronary ostial lesions. *Catheter Cardiovasc Interv* 2016;87:241–2. <https://doi.org/10.1002/ccd.26421>; PMID: 26876509.
- Kim JH, Kang DY, Ahn JM, et al. Optimal minimal stent area and impact of stent underexpansion in left main up-front 2-stent strategy. *Circ Cardiovasc Interv* 2024;17:e013006. <https://doi.org/10.1161/circinterventions.123.013006>; PMID: 38227699.
- Soeda T, Uemura S, Park SJ, et al. Incidence and clinical significance of poststent optical coherence tomography findings: one-year follow-up study from a multicenter registry. *Circulation* 2015;132:1020–9. <https://doi.org/10.1161/circulationaha.114.014704>; PMID: 26162917.
- Zhang M, Matsumura M, Usui E, et al. Intravascular ultrasound-derived calcium score to predict stent expansion in severely calcified lesions. *Circ Cardiovasc Interv* 2021;14:e010296. <https://doi.org/10.1161/circinterventions.120.010296>; PMID: 34665658.
- Yin D, Mintz GS, Song L, et al. In-stent stenosis characteristics and repeat stenting underexpansion: insights from optical coherence tomography. *EuroIntervention* 2020;16:e335–43. <https://doi.org/10.4244/eij-d-18-01191>; PMID: 31403461.
- Fujino A, Mintz GS, Matsumura M, et al. A new optical coherence tomography-based calcium scoring system to predict stent underexpansion. *EuroIntervention* 2018;13:e2182–9. <https://doi.org/10.4244/eij-d-17-00962>; PMID: 29400655.
- Min HS, Ryu D, Kang SJ, et al. Prediction of coronary stent underexpansion by pre-procedural intravascular ultrasound-based deep learning. *JACC Cardiovasc Interv* 2021;14:1021–9. <https://doi.org/10.1016/j.jcin.2021.01.033>; PMID: 33865741.
- De Maria GL, Scarsini R, Banning AP. Management of calcific coronary artery lesions: is it time to change our interventional therapeutic approach? *JACC Cardiovasc Interv* 2019;12:1465–78. <https://doi.org/10.1016/j.jcin.2019.03.038>; PMID: 31395217.
- Kawai K, Sato Y, Hokama JY, et al. Histology, OCT, and micro-CT evaluation of coronary calcification treated with intravascular lithotripsy: atherosclerotic cadaver study. *JACC Cardiovasc Interv* 2023;16:2097–108. <https://doi.org/10.1016/j.jcin.2023.06.021>; PMID: 37704295.
- Malik AO, Saxon JT, Spertus JA, et al. Hospital-level variability in use of intracoronary imaging for percutaneous coronary intervention in the United States. *J Soc Cardiovasc Angiogr Interv* 2023;2:100973. <https://doi.org/10.1016/j.jscai.2023.100973>; PMID: 39131640.
- Fujimura T, Matsumura M, Witzensbichler B, et al. Stent expansion indexes to predict clinical outcomes: an IVUS substudy from ADAPT-DES. *JACC Cardiovasc Interv* 2021;14:1639–50. <https://doi.org/10.1016/j.jcin.2021.05.019>; PMID: 34353595.
- Lee YJ, Zhang JJ, Mintz GS, et al. Impact of intravascular ultrasound-guided optimal stent expansion on 3-year hard clinical outcomes. *Circ Cardiovasc Interv* 2021;14:e011124. <https://doi.org/10.1161/circinterventions.121.011124>; PMID: 34665657.
- Romagnoli E, Ramazzotti V, Burzotta F, et al. Definition of optimal optical coherence tomography-based stent expansion criteria: in-stent minimum lumen area versus residual stent underexpansion. *Circ Cardiovasc Interv* 2022;15:e011496. <https://doi.org/10.1161/circinterventions.121.011496>; PMID: 36126136.
- Räber L, Mintz GS, Koskinas KC, et al. Clinical use of intracoronary imaging. Part 1: guidance and optimization of coronary interventions. An expert consensus document of the European Association of Percutaneous Cardiovascular Interventions. *Eur Heart J* 2018;39:3281–300. <https://doi.org/10.1093/eurheartj/ehy285>; PMID: 29790954.
- Sasi V, Szántó G, Achim A, et al. Combination of laser atherectomy and super high-pressure non-compliant balloon to treat stent under-expansion in cases of failed interventional options. *Under-Expansion* 2023;18:e23. <https://doi.org/10.15420/icr.2022.36>; PMID: 37538386.
- Rheude T, Rai H, Richardt G, et al. Super high-pressure balloon versus scoring balloon to prepare severely calcified coronary lesions: the ISAR-CALC randomised trial. *EuroIntervention* 2021;17:481–8. <https://doi.org/10.4244/eij-d-20-01000>; PMID: 33258774.
- Baudinet T, Seguy B, Cetrán L, et al. Bail-out therapy in ST-segment elevation myocardial infarction due to calcified lesion causing stent underexpansion: intravascular lithotripsy is in the lead. *J Cardiol Cases* 2021;23:264–6. <https://doi.org/10.1016/j.jccase.2020.12.014>; PMID: 34093904.
- Mangieri A, Nerla R, Castriota F, et al. Cutting balloon to optimize predilation for stent implantation: the COPS randomized trial. *Catheter Cardiovasc Interv* 2023;101:798–805. <https://doi.org/10.1002/ccd.30603>; PMID: 36841945.
- Wilson A, Ardehali R, Brinton TJ, et al. Cutting balloon inflation for drug-eluting stent underexpansion due to unrecognized coronary arterial calcification. *Cardiovasc*

- Revasc Med* 2006;7:185–8. <https://doi.org/10.1016/j.carrev.2006.05.005>; PMID: 16945827.
21. Song X, Adachi T, Kimura T, Saito N. Wolverine cutting balloon in the treatment of stent underexpansion in heavy coronary calcification: bench test using a three-dimensional printer and computer simulation with the finite-element method. *Cardiovasc Interv Ther* 2022;37:506–12. <https://doi.org/10.1007/s12928-021-00803-5>; PMID: 34374947.
  22. Spratt JC, Hung JD. Stent underexpansion in the CRUNCH registry: worth cracking? *EuroIntervention* 2022;18:529–30. <https://doi.org/10.4244/eij-e-22-00027>; PMID: 36134685.
  23. Alfonso F, Coughlan JJ, Giacoppo D, et al. Management of in-stent restenosis. *EuroIntervention* 2022;18:e103–23. <https://doi.org/10.4244/eij-d-21-01034>; PMID: 35656726.
  24. Kufner S, Joner M, Schneider S, et al. Neointimal modification with scoring balloon and efficacy of drug-coated balloon therapy in patients with restenosis in drug-eluting coronary stents: a randomized controlled trial. *JACC Cardiovasc Interv* 2017;10:1332–40. <https://doi.org/10.1016/j.jcin.2017.04.024>; PMID: 28683939.
  25. Tovar Forero MN, Sardella G, Salvi N, et al. Coronary lithotripsy for the treatment of underexpanded stents: the international, multicentre CRUNCH registry. *EuroIntervention* 2022;18:574–81. <https://doi.org/10.4244/eij-d-21-00545>; PMID: 35318955.
  26. Wañha W, Tomaniak M, Wañczura P, et al. Intravascular lithotripsy for the treatment of stent underexpansion: the multicenter IVL-DRAGON registry. *J Clin Med* 2022;11:1779. <https://doi.org/10.3390/jcm11071779>; PMID: 35407387.
  27. Achim A, Alampi C, Krivoshei L, Leibundgut G. In vitro effect of intravascular lithotripsy on the polymer of a drug-eluting stent. *EuroIntervention* 2022;18:e333–4. <https://doi.org/10.4244/eij-d-22-00300>; PMID: 35775926.
  28. Caminiti R, Vetta G, Parlavecchio A, et al. A systematic review and meta-analysis including 354 patients from 13 studies of intravascular lithotripsy for the treatment of underexpanded coronary stents. *Am J Cardiol* 2023;205:223–30. <https://doi.org/10.1016/j.amjcard.2023.07.144>; PMID: 37614144.
  29. Koide M, Inoue K, Matsuo A, Fujita H. Optical coherence tomography findings after longitudinal ablation for an underexpanded stent in a heavily calcified lesion: a case report. *BMC Cardiovasc Disord* 2016;16:241. <https://doi.org/10.1186/s12872-016-0419-8>; PMID: 27894264.
  30. Okamura A, Ito H, Fujii K. Rotational atherectomy is useful to treat restenosis lesions due to crushing of a sirolimus-eluting stent implanted in severely calcified lesions: experimental study and initial clinical experience. *J Invasive Cardiol* 2009;21:E191–6. PMID: 19805850.
  31. Ferri LA, Jabbar RJ, Giannini F, et al. Safety and efficacy of rotational atherectomy for the treatment of undilatable underexpanded stents implanted in calcific lesions. *Catheter Cardiovasc Interv* 2017;90:E19–24. <https://doi.org/10.1002/ccd.26836>; PMID: 27862848.
  32. Neupane S, Basir M, Tan C, et al. Feasibility and safety of orbital atherectomy for the treatment of in-stent restenosis secondary to stent under-expansion. *Catheter Cardiovasc Interv* 2021;97:2–7. <https://doi.org/10.1002/ccd.28675>; PMID: 31985132.
  33. Whiteside HL, Nagabandi A, Kapoor D. Safety and efficacy of stentablation with rotational atherectomy for the management of underexpanded and undilatable coronary stents. *Cardiovasc Revasc Med* 2019;20:985–9. <https://doi.org/10.1016/j.carrev.2019.01.013>; PMID: 30685339.
  34. Rawlins J, Din JN, Talwar S, O’Kane P. Coronary intervention with the excimer laser: review of the technology and outcome data. *Interv Cardiol* 2016;11:27–32. <https://doi.org/10.15420/icr.2016.2:2>; PMID: 29588701.
  35. Lee T, Shlofmitz RA, Song L, et al. The effectiveness of excimer laser angioplasty to treat coronary in-stent restenosis with peri-stent calcium as assessed by optical coherence tomography. *EuroIntervention* 2019;15:e279–88. <https://doi.org/10.4244/eij-d-18-00139>; PMID: 29769164.
  36. Latib A, Takagi K, Chizzola G, et al. Excimer laser lesion modification to expand non-dilatable stents: the ELLEMENT registry. *Cardiovasc Revasc Med* 2014;15:8–12. <https://doi.org/10.1016/j.carrev.2013.10.005>; PMID: 24290659.
  37. Hernández-Enríquez M, Campelo-Parada F, Lhermusier T, et al. Long-term outcomes of rotational atherectomy of underexpanded stents. A single center experience. *J Interv Cardiol* 2018;31:465–70. <https://doi.org/10.1111/joic.12491>; PMID: 29372576.
  38. Vrints C, Andreotti F, Koskinas KC, et al. 2024 ESC Guidelines for the management of chronic coronary syndromes. *Eur Heart J* 2024;45:3415–537. <https://doi.org/10.1093/eurheartj/ehae177>; PMID: 39210710.
  39. Scheller B, Hehrlein C, Bocksch W, et al. Treatment of coronary in-stent restenosis with a paclitaxel-coated balloon catheter. *N Engl J Med* 2006;355:2113–24. <https://doi.org/10.1056/NEJMoa061254>; PMID: 17101615.
  40. Giacoppo D, Alfonso F, Xu B, et al. Drug-coated balloon angioplasty versus drug-eluting stent implantation in patients with coronary stent restenosis. *J Am Coll Cardiol* 2020;75:2664–78. <https://doi.org/10.1016/j.jacc.2020.04.006>; PMID: 32466881.
  41. Erdogan E, Bajaj R, Lansky A, et al. Intravascular imaging for guiding in-stent restenosis and stent thrombosis therapy. *J Am Heart Assoc* 2022;11:e026492. <https://doi.org/10.1161/jaha.122.026492>; PMID: 36326067.
  42. Jaffe R, Halon DA, Shiran A, Rubinshtein R. Percutaneous treatment of aorto-ostial coronary lesions: current challenges and future directions. *Int J Cardiol* 2015;186:61–6. <https://doi.org/10.1016/j.ijcard.2015.03.161>; PMID: 25814346.
  43. Rathore S, Terashima M, Katoh O, et al. Predictors of angiographic restenosis after drug eluting stents in the coronary arteries: contemporary practice in real world patients. *EuroIntervention* 2009;5:349–54. <https://doi.org/10.4244/v5i3a55>; PMID: 19736160.
  44. Stewart JT, Ward DE, Davies MJ, Pepper JR. Isolated coronary ostial stenosis: observations on the pathology. *Eur Heart J* 1987;8:917–20. <https://doi.org/10.1093/oxfordjournals.eurheartj.a062359>; PMID: 3665950.
  45. Yamamoto K, Sato T, Salem H, et al. Ostial right coronary artery lesion morphology and outcomes after treatment with drug-eluting stents. *EuroIntervention* 2024;20:e207–15. <https://doi.org/10.4244/eij-d-23-00406>; PMID: 38343369.
  46. Boucek RJ, Takeshita R, Brady AH. Microanatomy and mechanical physical forces within the coronary arteries (man). *Anat Rec* 1965;153:233–41. <https://doi.org/10.1002/ar.1091530303>; PMID: 5880315.
  47. Mavromatis K, Ghazzal Z, Veledar E, et al. Comparison of outcomes of percutaneous coronary intervention of ostial versus nonostial narrowing of the major epicardial coronary arteries. *Am J Cardiol* 2004;94:583–7. <https://doi.org/10.1016/j.amjcard.2004.05.020>; PMID: 15342287.
  48. Hsieh IC, Chen CC, Chang SH, et al. Acute and long-term outcomes of drug-eluting stent implantations in aorto-ostial, left anterior descending artery-ostial, and nonostial lesions. *Catheter Cardiovasc Interv* 2013;82:727–34. <https://doi.org/10.1002/ccd.24943>; PMID: 23592601.
  49. Targoński R, Meyer-Szary J, Baścik B, et al. Optimal fluoroscopic viewing angles for stenting of the coronary aorto-ostial lesions. *Cardiol J* 2021;28:831–41. <https://doi.org/10.5603/CJ.a2021.0080>; PMID: 34355782.
  50. Kim SW, Mintz GS, Ohlmann P, et al. Comparative intravascular ultrasound analysis of ostial disease in the left main versus the right coronary artery. *J Invasive Cardiol* 2007;19:377–80. PMID: 17827506.
  51. Lawton JS, Tamis-Holland JE, Bangalore S, et al. 2021 ACC/AHA/SCAI guideline for coronary artery revascularization: executive summary: A report of the American College of Cardiology/American Heart Association joint committee on clinical practice guidelines. *Circulation* 2022;145:e4–e17. <https://doi.org/10.1161/cir.0000000000001039>; PMID: 34882436.
  52. Dadkhah R, Ungureanu C. Guide extension and optical coherence tomography, a new approach to study aorto-ostial coronary lesions: a case report. *Eur Heart J Case Rep* 2024;8:ytad624. <https://doi.org/10.1093/ehjcr/ytad624>; PMID: 38145109.
  53. De Rosa S, Polimeni A, De Velli G, et al. Reliability of instantaneous wave-free ratio (iFR) for the evaluation of left main coronary artery lesions. *J Clin Med* 2019;8:1143. <https://doi.org/10.3390/jcm8081143>; PMID: 31370353.
  54. Kurbaan AS, Kelly PA, Sigwart U. Cutting balloon angioplasty and stenting for aorto-ostial lesions. *Heart (Br Card Soc)* 1997;77:350–2. <https://doi.org/10.1136/hrt.77.4.350>; PMID: 9155615.
  55. Popma JJ, Dick RJ, Haudenschild CC, et al. Atherectomy of right coronary ostial stenoses: initial and long-term results, technical features and histologic findings. *Am J Cardiol* 1991;67:431–3. [https://doi.org/10.1016/0002-9149\(91\)90057-r](https://doi.org/10.1016/0002-9149(91)90057-r); PMID: 1994670.
  56. Popma JJ, Brogan WC, Pichard AD, et al. Rotational coronary atherectomy of ostial stenoses. *Am J Cardiol* 1993;71:436–8. [https://doi.org/10.1016/0002-9149\(93\)90448-l](https://doi.org/10.1016/0002-9149(93)90448-l); PMID: 8430634.
  57. Motwani JG, Raymond RE, Franco L, et al. Effectiveness of rotational atherectomy of right coronary artery ostial stenosis. *Am J Cardiol* 2000;85:563–7. [https://doi.org/10.1016/s0002-9149\(99\)00812-7](https://doi.org/10.1016/s0002-9149(99)00812-7); PMID: 11078268.
  58. Fuku Y, Kadota K, Toyofuku M, et al. Long-term outcomes of drug-eluting stent implantation after rotational atherectomy for left main coronary artery bifurcation lesions. *Am J Cardiol* 2019;123:1796–805. <https://doi.org/10.1016/j.amjcard.2019.03.002>; PMID: 30929770.
  59. Quillot M, Carrié D, Lhermusier T, et al. Short- and mid-term prognosis of patients undergoing rotational atherectomy in aortoostial coronary lesions in left main or right coronary arteries. *J Interv Cardiol* 2019;2019:9012787. <https://doi.org/10.1155/2019/9012787>; PMID: 31772550.
  60. Sakakura K, Ito Y, Shibata Y, et al. Clinical expert consensus document on rotational atherectomy from the Japanese association of cardiovascular intervention and therapeutics. *Cardiovasc Interv Ther* 2021;36:1–18. <https://doi.org/10.1007/s12928-020-00715-w>; PMID: 33079355.
  61. Riley RF, Patel MP, Abbott JD, et al. SCAI expert consensus statement on the management of calcified coronary lesions. *J Soc Cardiovasc Angiogr Interv* 2024;3:101259. <https://doi.org/10.1016/j.jscai.2023.101259>; PMID: 39132214.
  62. Lee MS, Shlofmitz E, Kong J, et al. Outcomes of patients with severely calcified aorto-ostial coronary lesions who underwent orbital atherectomy. *J Interv Cardiol* 2018;31:15–20. <https://doi.org/10.1111/joic.12432>; PMID: 28870003.
  63. Hill JM, Kereiakes DJ, Shlofmitz RA, et al. Intravascular lithotripsy for treatment of severely calcified coronary artery disease. *J Am Coll Cardiol* 2020;76:2635–46. <https://doi.org/10.1016/j.jacc.2020.09.603>; PMID: 33069849.
  64. Lee MS, Kereiakes DJ, Shlofmitz RA, et al. Intravascular lithotripsy for calcified left main artery disease. *J Soc Cardiovasc Angiogr Interv* 2023;2:101126. <https://doi.org/10.1016/j.jscai.2023.101126>; PMID: 39129890.
  65. Salazar CH, Gonzalo N, Aksoy A, et al. Feasibility, safety, and efficacy of intravascular lithotripsy in severely calcified left main coronary stenosis. *JACC Cardiovasc Interv* 2020;13:1727–9. <https://doi.org/10.1016/j.jcin.2020.04.022>; PMID: 32703602.
  66. Rubinshtein R, Ben-Dov N, Halon DA, et al. Geographic miss with aorto-ostial coronary stent implantation: insights from high-resolution coronary computed tomography angiography. *EuroIntervention* 2015;11:301–7. <https://doi.org/10.4244/eij/v11i3a57>; PMID: 24694540.
  67. Yamamoto K, Sato T, Salem H, et al. Mechanisms and treatment outcomes of ostial right coronary artery in-stent restenosis. *EuroIntervention* 2023;19:e383–93. <https://doi.org/10.4244/eij-d-23-00107>; PMID: 37283548.
  68. De Silva K, Li Kam Wa ME, Wells T, et al. The everolimus eluting Synergy Megatron™ drug-eluting stent platform: early outcomes from the European Synergy Megatron™ Implants registry. *Catheter Cardiovasc Interv* 2023;102:1222–8. <https://doi.org/10.1002/ccd.30902>; PMID: 37948428.
  69. Tsunoda T, Nakamura M, Wada M, et al. Chronic stent recoil plays an important role in restenosis of the right coronary ostium. *Coron Artery Dis* 2004;15:39–44. <https://doi.org/10.1097/00019501-200402000-00006>; PMID: 15201619.
  70. Funayama N, Muratsubaki S, Ito R, et al. Drug-coated balloons versus drug-eluting stents for coronary de novo lesions in dialysis patients. *Heart Vessels* 2023;38:300–8. <https://doi.org/10.1007/s00380-022-02169-x>; PMID: 36045267.
  71. Jakabcin J, Spacek R, Bystron M, et al. Long-term health outcome and mortality evaluation after invasive coronary treatment using drug eluting stents with or without the IVUS guidance. Randomized control trial. Home DES IVUS. *Catheter Cardiovasc Interv* 2010;75:578–83. <https://doi.org/10.1002/ccd.22244>; PMID: 19902491.
  72. Tian NL, Gami SK, Ye F, et al. Angiographic and clinical comparisons of intravascular ultrasound- versus angiography-guided drug-eluting stent implantation for patients with chronic total occlusion lesions: two-year results from a randomised AIR-CTO study. *EuroIntervention* 2015;10:1409–17. <https://doi.org/10.4244/eij/v10i12a245>; PMID: 25912391.
  73. Kim BK, Shin DH, Hong MK, et al. Clinical impact of intravascular ultrasound-guided chronic total occlusion intervention with zotarolimus-eluting versus biolimus-eluting stent implantation: randomized study. *Circ Cardiovasc Interv* 2015;8:e002592. <https://doi.org/10.1161/circinterventions.115.002592>; PMID: 26156151.
  74. Meneveau N, Souteyrand G, Motreff P, et al. Optical coherence tomography to optimize results of percutaneous coronary intervention in patients with non-ST-elevation acute coronary syndrome: results of the multicenter, randomized DOCTORS study (does optical coherence tomography optimize results of stenting). *Circulation* 2016;134:906–17. <https://doi.org/10.1161/circulationaha.116.024393>; PMID: 27573032.
  75. Kala P, Cervinka P, Jakl M, et al. OCT guidance during stent implantation in primary PCI: A randomized multicenter study with nine months of optical coherence tomography follow-up. *Int J Cardiol* 2018;250:98–103. <https://doi.org/10.1016/j.ijcard.2017.10.059>; PMID: 29079414.
  76. Hong SJ, Kim BK, Shin DH, et al. Effect of intravascular ultrasound-guided vs angiography-guided everolimus-eluting stent implantation: the IVUS-XPL randomized clinical trial. *JAMA* 2015;314:2155–63. <https://doi.org/10.1001/jama.2015.15454>; PMID: 26556051.
  77. Ali ZA, Maehara A, Généreux P, et al. Optical coherence tomography compared with intravascular ultrasound and

- with angiography to guide coronary stent implantation (ILUMIEN III: OPTIMIZE PCI): a randomised controlled trial. *Lancet* 2016;388:2618–28. [https://doi.org/10.1016/S0140-6736\(16\)31922-5](https://doi.org/10.1016/S0140-6736(16)31922-5); PMID: 27806900.
78. Zhang J, Gao X, Kan J, et al. Intravascular ultrasound versus angiography-guided drug-eluting stent implantation: the ULTIMATE trial. *J Am Coll Cardiol* 2018;72:3126–37. <https://doi.org/10.1016/j.jacc.2018.09.013>; PMID: 30261237.
79. Chamié D, Costa JR, Damiani LP, et al. Optical coherence tomography versus intravascular ultrasound and angiography to guide percutaneous coronary interventions: the iSIGHT randomized trial. *Circ Cardiovasc Interv* 2021;14:e009452. <https://doi.org/10.1161/circinterventions.120.009452>; PMID: 33685212.
80. Lee JM, Choi KH, Song YB, et al. Intravascular imaging-guided or angiography-guided complex PCI. *N Engl J Med* 2023;388:1668–79. <https://doi.org/10.1056/NEJMoa2216607>; PMID: 36876735.
81. Ali ZA, Landmesser U, Maehara A, et al. Optical coherence tomography-guided versus angiography-guided PCI. *N Engl J Med* 2023;389:1466–76. <https://doi.org/10.1056/NEJMoa2305861>; PMID: 37634188.
82. Holm NR, Andreasen LN, Neghabat O, et al. OCT or angiography guidance for PCI in complex bifurcation lesions. *N Engl J Med* 2023;389:1477–87. <https://doi.org/10.1056/NEJMoa2307770>; PMID: 37634149.
83. Kang DY, Ahn JM, Yun SC, et al. Optical coherence tomography-guided or intravascular ultrasound-guided percutaneous coronary intervention: the OCTIVUS randomized clinical trial. *Circulation* 2023;148:1195–206. <https://doi.org/10.1161/circulationaha.123.066429>; PMID: 37634092.